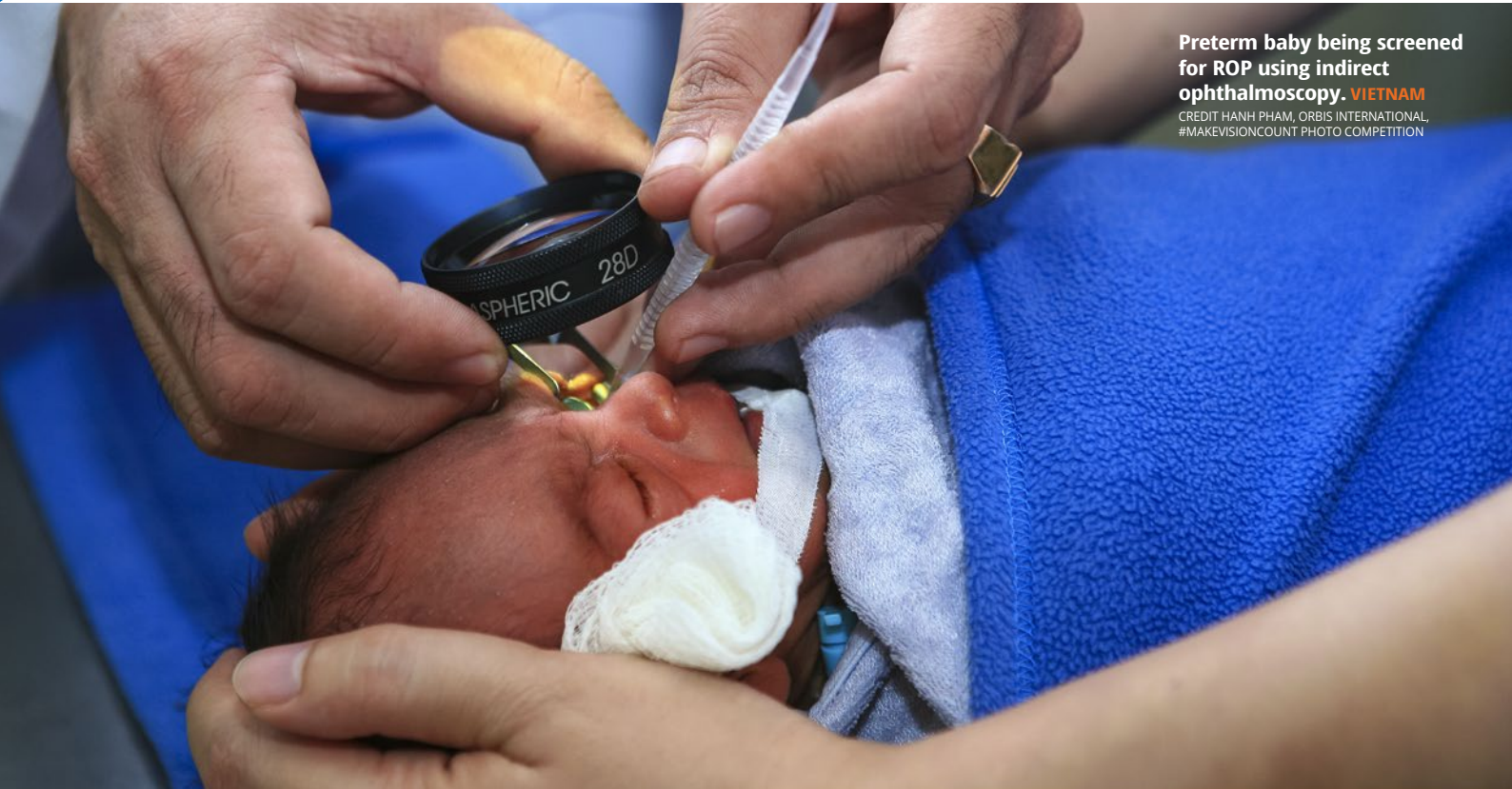

Community Eye Health Journal



Preterm baby being screened for ROP using indirect ophthalmoscopy. VIETNAM

CREDIT HANH PHAM, ORBIS INTERNATIONAL, #MAKEVISIONCOUNT PHOTO COMPETITION

Retinopathy of prematurity: it is time to take action



Clare Gilbert

Professor of International Eye Health and Co-director: International Centre for Eye Health, London School of Hygiene & Tropical Medicine, London, UK.



Hannah Blencowe

Assistant Professor: London School of Hygiene & Tropical Medicine, UK.

Retinopathy of prematurity affects babies born preterm: before 37 weeks of gestation. Unless these babies are carefully managed, they can become visually impaired or blind. But there is hope: the condition can be prevented and treated.

Every year, an estimated 15 million babies are born preterm (normal gestation is 37–42 weeks).¹ Approximately 20,000 of these babies will become blind from retinopathy of prematurity (ROP) every year, and an additional 12,300 will be left with visual impairment.²

Countries with the highest number of preterm births are India, China, Nigeria, Pakistan and Indonesia. East Asia, South East Asia, and the Pacific are the regions with the highest number of preterm babies who survive, and the highest number who develop visual loss from ROP (Figure 1).² However, all regions of the world are now affected.

For almost 80 years, it has been known that preterm infants can become blind from ROP: it was first described in the United States of America as retrolental fibroplasia. The main risk factors have also been known for a long time. Urgent laser treatment has now been shown to be effective, and screening and treatment programmes have reduced blindness in children from ROP in many high-income countries. So why is ROP an important cause of blindness in children in many low- and middle-income countries? There are four main reasons.

- 1 Increased services for sick and preterm infants mean that many more preterm babies are now surviving.

Continues overleaf ➤





About this issue

More neonatal services worldwide means that more babies are surviving, including those born preterm. Sadly, many of these babies will go blind from retinopathy of prematurity. But there is hope: ROP can be prevented and treated. In this issue, we offer up-to-date information and guidance for each member of the clinical team involved in the care of preterm babies, including neonatologists, nurses, and ophthalmologists, and emphasise the importance of involving parents in every aspect of their child's care. We hope that you will be inspired to share this knowledge within your team and with others in the neonatology unit and thereby help to save the sight of many young children.

Contents

- 45 Retinopathy of prematurity: it is time to take action**
Clare Gilbert and Hannah Blencowe
- 49 How does ROP develop?**
Andrea Molinari, Dan Weaver and Subhadra Jalali
- 50 Preventing sight-threatening ROP: a neonatologist's perspective**
Ashok Deorari and Brian A Darlow
- 53 Preventing sight-threatening ROP: the role of nurses in reducing the risk**
Ana Quiroga and Sarah Moxon
- 55 Classifying retinopathy of prematurity**
Andrea Molinari, Dan Weaver and Subhadra Jalali
- 57 Screening for ROP**
Graham Quinn and Clare Gilbert
- 59 Treating ROP: how and when**
Graham Quinn and Clare Gilbert
- 60 Involving the parents of preterm babies**
Julie Flanagan, Erika Maka and Cristina Nitulescu
- 62 Following up children born preterm**
P Vijayalakshmi and Clare Gilbert
- 65 TRACHOMA: Reaching remote Amazonian communities to eliminate trachoma**
Julian Trujillo Trujillo, Tim Jesudason and Girija Sankar
- 66 Test your knowledge and understanding**
- 67 Picture quiz**
- 67 Announcements and resources**
- 68 KEY MESSAGES**

Prematurity is responsible for 18% of under-5 mortality worldwide³, and governments have been motivated to address this by increasing the availability of neonatal services.

- 2 The quality of the neonatal care babies receive can be less than ideal in some areas, which increases the risk of the severe, sight-threatening stages of ROP.
- 3 Not all preterm infants at risk of ROP are screened, or screening is inadequate, and so babies requiring treatment are not identified.
- 4 Urgent laser treatment, which is highly effective in most cases, may not be delivered in time, or it may not be adequately delivered.

Which babies are most at risk?

In the womb, the developing fetus is in a stable, warm, quiet, and dark environment, and is suspended in fluid and therefore able to move. Nutrients and oxygen are continuously supplied via the umbilical cord. Replicating this level of stability in babies who are 'born too soon' is a great challenge.

The following babies are at risk of ROP:

- Babies who are extremely premature, i.e., born more than 8 weeks early with a gestational age of less than 32 weeks. These babies are most at risk: the more preterm the baby, the greater the risk.
- Babies with a gestational age of 32–36 weeks (4–8 weeks premature), if they receive poor neonatal care.
- Babies who have a low birth weight (<1,500 g).
- Babies with a higher birthweight, if they receive poor neonatal care.
- Babies who are given too much oxygen and for too long (high blood oxygen levels damage the developing blood vessels in the retina).

The risk of ROP is increased by:

- Inadequate nutrition with poor weight gain during the first few weeks of life.
- Infection during the first few weeks.
- Anything that makes babies unstable: pain, poor temperature control and not keeping the baby comfortable and supported in the cot or incubator.

Community Eye Health Journal
VOLUME 30 • NUMBER 99 • 2017



Editor
Elmien Wolvaardt
editor@cehjournal.org
Consulting editor for Issue 99
Clare Gilbert
Clare.gilbert@lshtm.ac.uk

Editorial assistant
Anita Shah
anita.shah@lshtm.ac.uk

Editorial committee
Nick Astbury
Matthew Burton
Sally Crook
Allen Foster
Clare Gilbert
Hannah Kuper
Fatima Kyari
Janet Marsden
Priya Morjaria
G V Murthy
Daksha Patel
Noela Prasad

Babar Qureshi
Serge Resnikoff
Richard Wormall
David Yorston

Regional consultants
Hannah Faal (AFR)
Kovin Naidoo (AFR)
Wanjiku Mathenge (AFR)
Van Lansingh (AMR)
Andrea Zin (AMR)
Ian Murdoch (EUR)
Janos Nemeth (EUR)
GVS Murthy (SEAR)
R Thulsiraj (SEAR)
Babar Qureshi (EMR)
Mansur Rabiou (EMR)
Leshan Tan (WPR)
Hugh Taylor (WPR)

Proofreader Caroline Thaug
Design Lance Bellers
Printing Newman Thomson

CEHJ online
Visit the *Community Eye Health Journal* online. All back issues are available as HTML and PDF.
Visit: www.cehjournal.org

Online edition and newsletter
web@cehjournal.org

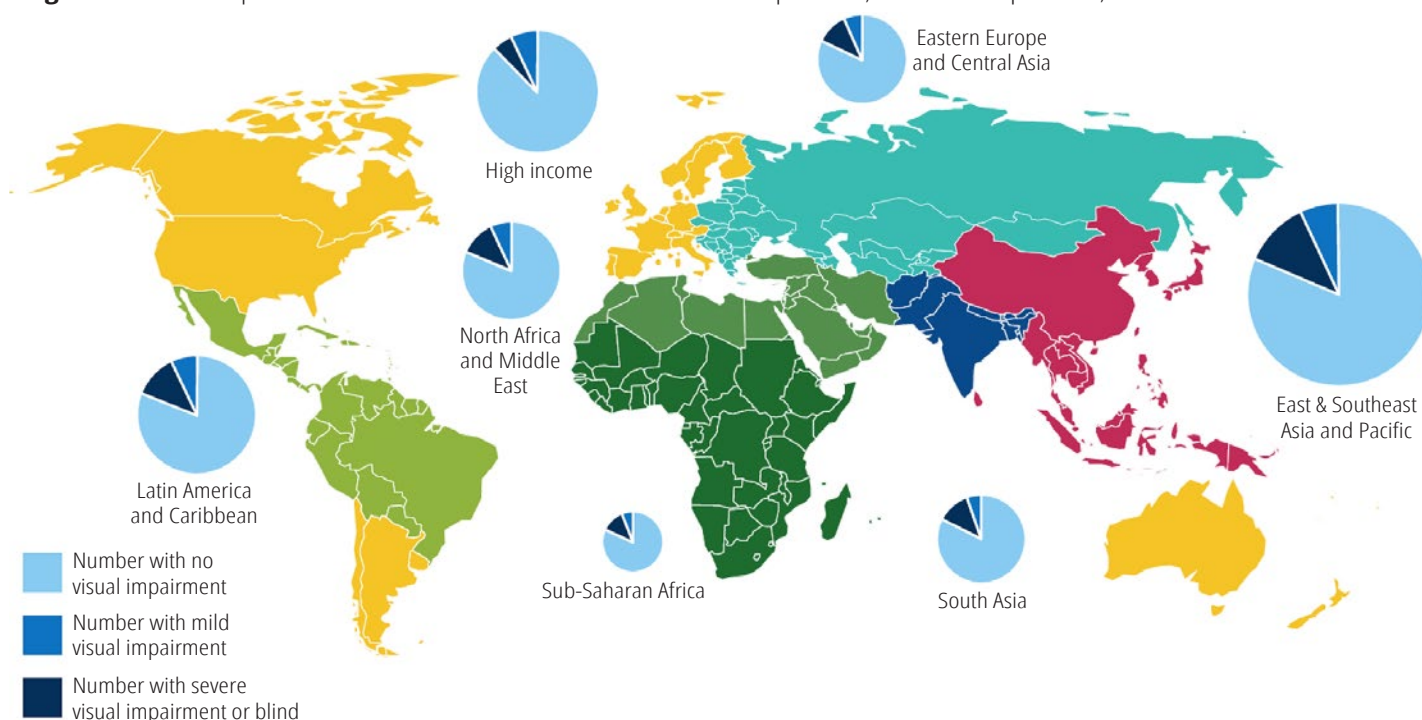
Please support us
We rely on donations/subscriptions from charities and generous individuals to carry out our work. We need your help.

Subscriptions in high-income countries cost UK £100 per annum.

Contact Anita Shah
admin@cehjournal.org

or visit our website:
www.cehjournal.org/donate

Figure 1 Number of preterm infants who survived in 2010 without visual impairment, with visual impairment, and blind. From Blencowe *et al.*¹



Exposure to postnatal risk factors is higher in neonatal units where:

- Staff members are inadequately trained.
- There are too few staff members.
- There is inadequate equipment to deliver and monitor oxygen.
- Mothers are not encouraged to play a role in caring for and giving their babies breast milk.

How can visual loss be prevented?

Premature birth is very difficult to predict or control, but good neonatal care, screening, and urgent laser treatment can reduce the number of infants who become blind or visually impaired.

The articles on pp. 50–54 explain how doctors and nurses can reduce the risk of ROP using the POINTS of Care system: controlling **pain**, careful use of **oxygen**,

preventing **infection**, improving **nutrition** by offering babies breast milk, good **temperature** control and **supportive** practices to keep babies comfortable and stable, such as kangaroo care.

Screening for ROP is needed to detect babies who develop the serious, sight-threatening stages of ROP (pp. 57–58). Screening is usually conducted by an experienced ophthalmologist in the neonatal unit, using indirect ophthalmoscopy. Who to screen, and when to screen, depends on many factors, including the quality of the neonatal care provided. Where care is suboptimal, bigger, more mature babies should be screened as they can also develop sight-threatening ROP.

Since ROP is not present at birth, but develops during the first few weeks of life, the first screening examination should take place no later than 30 days

Continues overleaf ➤

Subscriptions

Readers in low- and middle-income countries receive the journal free of charge. Send your name, occupation, and postal address to the address below. French, Spanish, and Chinese editions are available. To subscribe online, visit www.cehjournal.org/subscribe

Address for subscriptions

Anita Shah, International Centre for Eye Health, London School of Hygiene and Tropical Medicine, Keppel Street, London WC1E 7HT, UK.

Tel +44 (0)207 958 8336

Email admin@cehjournal.org

Correspondence articles

We accept submissions of 800 words about readers' experiences.

Contact Anita Shah:

correspondence@cehjournal.org

Published by the International Centre for Eye Health, London School of Hygiene & Tropical Medicine.

Unless otherwise stated, authors share copyright for articles with the Community Eye Health Journal. Illustrators and photographers retain copyright for images published in the journal.

Unless otherwise stated, journal content is licensed under a Creative Commons Attribution-NonCommercial (CC BY-NC) license which permits unrestricted use, distribution, and reproduction in any medium for non-commercial purposes, provided that the copyright holders are acknowledged.

ISSN 0953-6833

Disclaimer

Signed articles are the responsibility of the named authors alone and do not necessarily reflect the views of the London School of Hygiene & Tropical Medicine (the School). Although every effort is made to ensure accuracy, the School does not warrant that the information contained in this publication is complete and correct and shall not be liable for any damages incurred as a result of its use.

The mention of specific companies or of certain manufacturers' products does not imply that they are endorsed or recommended by the School in preference to others of a similar nature that are not mentioned. The School does not endorse or recommend products or services for which you may view advertisements in this Journal.

The *Community Eye Health Journal* is sponsored by:


**THE QUEEN ELIZABETH
DIAMOND JUBILEE TRUST**

CONRAD N.

FOUNDATION


cbm
together we can do more


**LIGHT
FOR THE WORLD**


orbis


iTi
International Trachoma Initiative


Sightsavers


**The Fred Hollows
Foundation**

after birth. Follow-up screening is often needed, and may be done after the baby has been discharged from the neonatal unit. Each country must decide which screening criteria apply to their setting.

All babies who develop the sight-threatening stages of ROP must be treated urgently: within 48–72 hours.

Follow-up of all preterm babies is important, as they are at greater risk of other conditions which can lead to visual loss (pp. 62–64). These are more common if the baby had ROP, particularly if treatment was given. The commonest condition is refractive error, including myopia, which can be severe and develop before the age of 12 months. Strabismus and cerebral visual impairment are also more common than in children born at term.

New developments

There have been several new and important developments. These include the recognition that care of preterm babies during the first hour after birth is extremely important (this has been called the 'first golden hour'). Kangaroo care, where the baby is placed securely on the chest of their mother or father (see below), can also play an important role in keeping preterm babies stable. New imaging systems for ROP are likely to change the way screening is undertaken, and new treatments for ROP are also being investigated. All of these topics are discussed in more detail in this issue.

What can eye care providers do?

Nurses, neonatologists, ophthalmologists and parents all play a vital role in reducing the risk of ROP. However, in many low- and middle-income countries, lack of awareness about ROP is an issue, as it is not yet included in many training curricula, including those for paediatricians and ophthalmologists. There is also lack of awareness among the general population.

Ophthalmologists can visit the neonatal unit in the hospital, or a unit nearby, to find out whether preterm babies are admitted and survive, and whether babies are being screened for ROP. If not, they could set up a service (after being adequately trained).^{4,5}

Ophthalmologists and optometrists can play an active role in following up infants and children who were born preterm to detect and manage refractive errors and other conditions, such as strabismus (pp. 62–64).

To improve awareness of ROP, eye care providers can distribute copies of relevant articles in this issue to colleagues, including obstetricians, midwives, neonatologists, neonatal nurses, paediatricians, ophthalmologists, and optometrists. The images are also helpful for educating parents.

Some infants with the advanced stages of ROP may retain a proportion of useful residual vision and will benefit from low vision services. Others may be completely blind. Since blindness of early onset can lead to developmental delay, these children should be referred for rehabilitation.

Summary

A lot is now known about ROP in terms of the risk factors, which babies are most at risk and the natural history. In ROP there is only a very narrow time window in which to detect and treat babies who have the sight-threatening stages of ROP, i.e., within the first few weeks and months of life. Long-term follow up is essential. Many different people can play a role in preventing blindness and visual impairment from ROP and its long term complications. Those providing low vision and rehabilitation services can help to improve children's future quality of life. Parents can play a critically important role at all stages of care.

References

- 1 March of Dimes, PMNCH, Save the Children, WHO. Born Too Soon: The Global Action Report on Preterm Birth. Eds CP Howson, MV Kinney, JE Lawn. World Health Organization. Geneva, 2012.
- 2 Blencowe J, Lawn JE, Vazquez T, Fielder A and Gilbert C. Beyond newborn survival: Paper 3. Preterm associated visual impairment and estimates of retinopathy of prematurity at regional and global level for 2010. *Pediatr Res* 2013;54:36–49.
- 3 Levels & Trends in Child Mortality. Report 2015. Estimates Developed by the UN Inter-agency Group for Child Mortality Estimation.
- 4 Jalali S, Anand R, Kumar H, Dogra MR, Azad R, Gopal L. Programme planning and screening strategy in retinopathy of prematurity. *Indian J Ophthalmol* 2003 Mar;51(1):89–99.
- 5 Darlow B et al. Setting up and improving retinopathy of prematurity programs. *Clin Perinatol* 2013 40:215–227.

Did you know?

Sharing the articles in this issue can help to raise awareness of ROP. Copying and reuse of journal articles and images for such purposes is not only permitted, but encouraged. Online copies of all articles are available free of charge from www.cehjournal.org and high-resolution images are available (also free of charge) from www.flickr.com/photos

Kangaroo care

Kangaroo care helps to recreate an ideal environment for preterm infants. The infant is placed against the skin on the chest of the mother or father and held in place with a wrap. This can start as soon as the baby is stable, even if they have a medical condition. It can be intermittent or continuous.

Kangaroo care helps to keep babies stable and warm, increases maternal breast milk production and encourages breast feeding. This improves weight gain and growth which lowers the risk of mortality; there is also a lower risk of infection.

Kangaroo care promotes bonding between parents and their child

and can help to reduce parental depression.

Some neonatal units have a dedicated ward for kangaroo care. Parents and their babies go there after leaving intensive care and before they are ready to go home.

The World Health Organization (WHO) has produced a practical guide to kangaroo care which is available from this link:

<http://tinyurl.com/kangarooMC>

Evidence about the effectiveness of kangaroo care to reduce mortality and morbidity in preterm infants is available from: <https://www.ncbi.nlm.nih.gov/pubmed/27552521>



BIJU RAJU

Ophthalmologist Biju Raju gave his son kangaroo care. Dr Raju screened (and treated) his son for ROP, despite initial protests from the neonatology team. INDIA

How does ROP develop?



Andrea Molinari
Pediatric
Ophthalmologist:
Hospital
Metropolitano,
Av. Mariana de Jesus
Oe-8, Quito, Ecuador.



Dan Weaver
Pediatric
Ophthalmologist:
Billings Clinic,
Billings, Montana,
USA.



Subhadra Jalali
Deputy Director:
Newborn Eye Health
Alliance (NEHA) and
Director, Quality: LV
Prasad Eye Institute,
Hyderabad, India.

Retinopathy of prematurity can develop when babies are born before their retinal blood vessels are fully formed.

In babies who are born at full term (between 37 and 42 weeks of gestation), the retinal blood vessels are fully developed and reach the edge of the retina: the ora serrata (Figure 1).

In babies who are born preterm (before 37 weeks), the retinal blood vessels are not fully formed and do not reach the ora serrata (Figure 2). If a preterm baby is examined a week or so after birth, it is possible to see whether the blood vessels are mature and have reached the ora serrata, or whether they are immature; i.e., the peripheral retina is not vascularised. If babies receive good neonatal care,

the retinal blood vessels continue to grow normally. If the neonatal environment is not ideal, particularly if oxygen levels have been higher or more variable than they should be, the retinal blood vessels stop growing. A visible line or a ridge then forms and the blood vessels may start to multiply (proliferate) abnormally. The visible line, ridge and proliferating blood vessels are all signs of retinopathy of prematurity (ROP). See Figure 3.

In 5–10% of premature babies, ROP progresses and can lead to retinal detachment (Figure 4). This causes irreversible blindness, often in both eyes.

Figure 1 In the full-term eye, the retinal blood vessels are fully developed

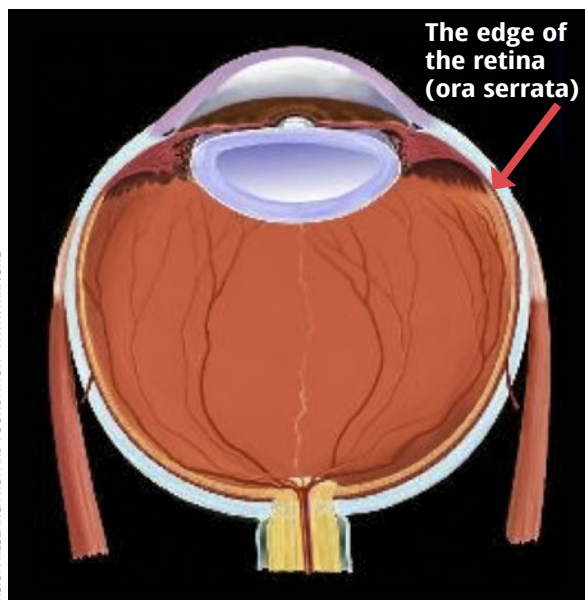


Figure 2 In the preterm eye, the retinal blood vessels are not fully developed

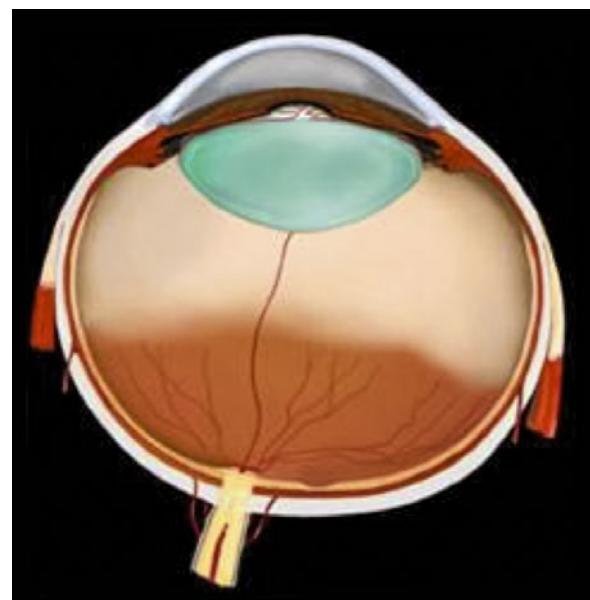


Figure 3 ROP occurs at the junction between the vascularised and unvascularised retina

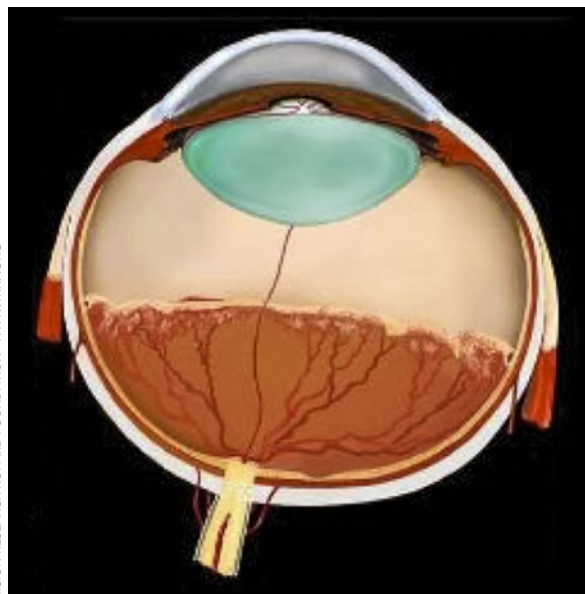
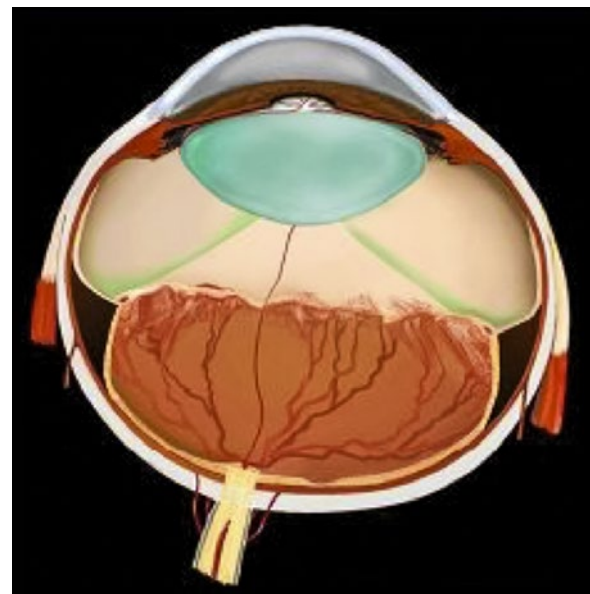


Figure 4 Advanced ROP with partial retinal detachment



Preventing sight-threatening ROP: a neonatologist's perspective



Ashok Deorari

Professor:
Department of
Paediatrics, WHO
Collaborating Centre
for Training and
Research in Newborn
Care), All India
Institute Of Medical
Sciences, New Delhi,
India.



Brian A Darlow

Emeritus Professor
of Paediatrics:
University of Otago,
Christchurch, New
Zealand.

Neonatal care during the first hours and weeks of life determines a preterm baby's chances of avoiding retinopathy of prematurity and its complications. Oxygen management and low-cost interventions make all the difference.



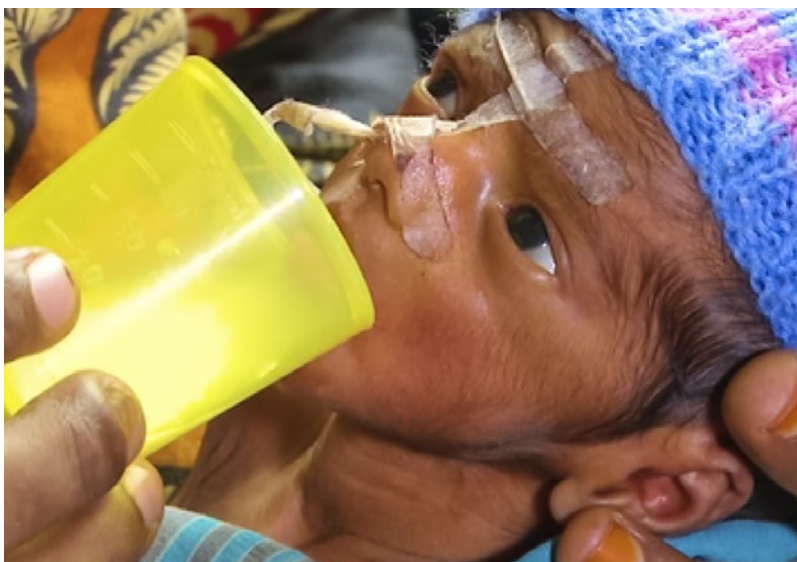Supportive care practices, such as kangaroo care, are central to the management of infants who are at risk of ROP.

It is recognised that the number of new cases (incidence) of retinopathy of prematurity (ROP) varies considerably between different intensive care neonatal units, even those with similar characteristics in terms of the equipment and clinical staff available. Whilst there may be several other reasons for this, one reason we can be certain about is that there are differences in newborn care practices between units. Routinely implementing standard interventions that are known to prevent ROP will improve outcomes.

Preventing ROP before delivery

A course of steroids, given to mothers likely to give birth prematurely, improves survival and reduces the complications of prematurity, including ROP. Antenatal steroids should be routine for mothers likely to give birth to a baby of less than 35 weeks' gestation.

If preterm babies cannot be breastfed, they can be given small amounts of breast milk by cup.



Risk factors for ROP

In addition to ROP, preterm babies can have other serious complications, including changes in the brain, chronic lung disease, and severe infection of the gut. Interventions and better care practices which aim to prevent one problem, for example infection, frequently also reduce the incidence of another, such as ROP.

The main risk factor for ROP is prematurity, but this is difficult to prevent. However, other factors such as exposure to too much oxygen, infection, and poor weight gain after birth also increase the risk. Controlling these factors requires high quality neonatal care, which can be summarised as POINTS of Care:

- Pain control
- Oxygen management
- Infection control
- Nutrition
- Temperature control
- Supportive care

Before describing how these risk factors can be controlled during a baby's stay in the neonatal unit, it is important to understand the following:

- How to deliver and monitor oxygen levels in the blood
- How to prevent ROP immediately after preterm birth.

Delivering and monitoring oxygen levels

Oxygen saturation (SpO_2) is a measurement of the proportion of haemoglobin in arterial blood that is carrying oxygen. The air we breathe is 21% oxygen and – in healthy adults – this is enough to ensure that all the haemoglobin in the arterial blood is carrying oxygen (i.e., an SpO_2 of 100%). SpO_2 can be measured at any age using a pulse oximeter. For preterm babies,

Figure 1 A pulse oximeter is attached to a preterm baby's foot

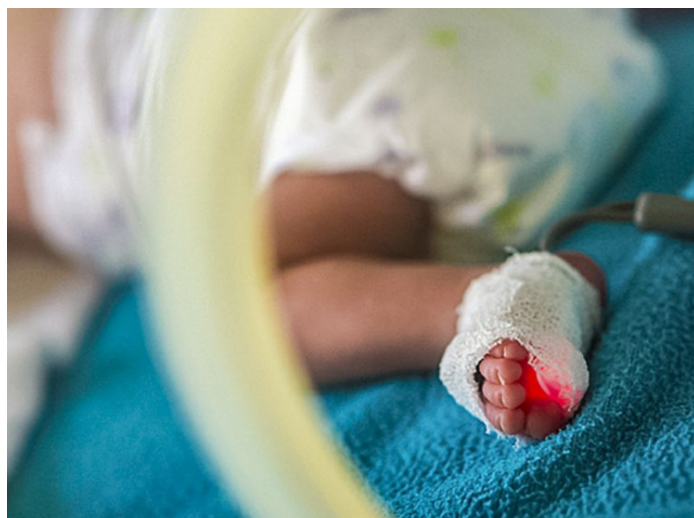
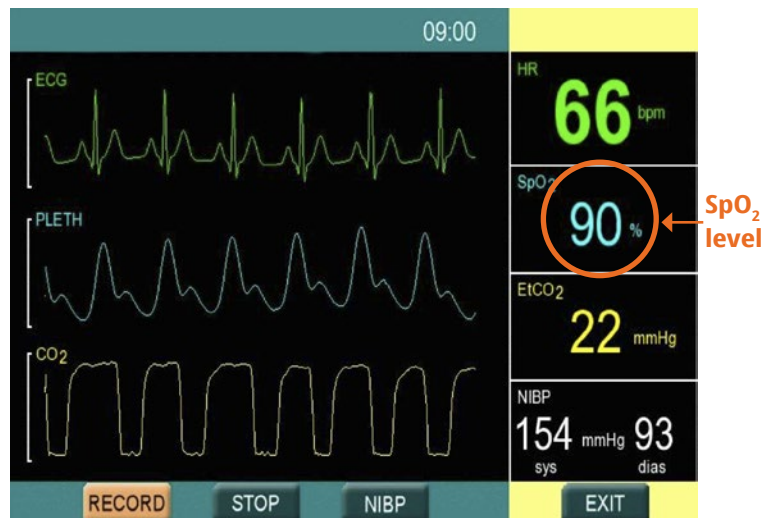
Figure 2 The oxygen saturation is expressed as a percentage (90%)



the probe is usually attached to the foot (Figure 1). The SpO₂ level is shown on a display monitor (Figure 2).

In the womb, a baby's SpO₂ is less than 100%; it is usually around 50–70%. This is entirely normal. After birth, the SpO₂ in a healthy baby increases gradually to around 100% at 10 minutes.

If the saturation is lower than it should be at any time during neonatal care, additional oxygen can be given at varying concentrations. This is called supplemental oxygen. In preterm babies, an SpO₂ of 95–100% can damage developing blood vessels in the retina, leading to ROP, and can damage the lungs and brain. A low SpO₂ can also lead to brain damage. Careful administration and oxygen monitoring from immediately after birth are therefore essential in preterm babies. Alarms on the monitor should be set so that they sound if the SpO₂ levels are too high (95% or above) or too low (88% or less). This alerts the neonatal team so that they can address the problem as quickly as possible.

Preventing ROP during the first hour after preterm birth

The first hour of life has been called the 'golden hour' because several low-cost interventions greatly improve outcomes (Table 1). These include delayed clamping of the umbilical cord, keeping babies warm, and gentle respiratory support. Protocols are essential so that staff can work as a co-ordinated team. Routine resuscitation of term and moderate-to-late preterm babies begins with gentle ventilation with a bag and mask, using air.

Preterm infants <32 weeks should receive ventilation with a bag and mask and 30% oxygen, modifying the concentration of oxygen given to meet time-specific oxygen saturation targets (Table 2). Giving 100% oxygen is not necessary for most preterm babies. Ideally, there should be equipment to mix air and oxygen (blenders) in the delivery room. If the baby is not breathing well, or the heart rate is dropping, the concentration of oxygen given can be increased to 100% and then reduced as soon as possible.

Preventing ROP in the neonatal unit: POINTS of Care

There are a number of low-cost, effective practices that can reduce the risk of ROP. Many of these 'POINTS of Care' (see below and in Table 3, overleaf) help to keep babies stable and reduce wide fluctuations in blood oxygen levels so that extra oxygen is not needed.

Pain makes babies unstable. It can increase the need for oxygen and worsen respiratory distress. See Table 3.

Oxygen. The World Health Organization recommends that for preterm babies with a gestational age of less than 32 weeks, the SpO₂ should be not be lower

Continues overleaf ➤

Table 1 Labour ward and delivery room interventions

Intervention	Explanation
Antenatal corticosteroids for preterm births (< 35 weeks' gestation)	Reduces mortality, the severity of respiratory distress and other complications
Delay clamping the umbilical cord by 30–60 seconds in vigorous preterm infants	Decreases some complications (IVH, NEC) and reduces the need for blood transfusion
Keep preterm babies warm. Use a plastic bag or occlusive wrapping (Figure 2, p. 54)	Maintaining normal temperature (36.5–37.2 °C) reduces the risk of severe ROP and other complications
Gentle respiratory management	This avoids injury to the lungs. Most newborns are not pink at birth. If they are breathing well, the colour will improve in 5–10 minutes

Table 2 Target oxygen saturation levels (SpO₂) in preterm infants during the first 10 minutes after birth

Time after birth	Oxygen saturation* (range)
2 min	55–75%
3 min	65–80%
4 min	70–85%
5 min	80–90%
10 min	85–95%

*The proportion of haemoglobin in arterial blood that is carrying oxygen

Table 3 Neonatal care best practices

Intervention	Explanation
Pain: Avoid and prevent painful episodes	Reduce unnecessary painful procedures. Anticipate pain and prevent it by swaddling and use of oral sucrose or glucose
Oxygen management	Ensure that the oxygen saturation is between 89% and 94%
Infection control	Apply infection control procedures, including hand washing by all
Nutrition: Improved nutrition with breast milk	Use mothers' own breast milk but provide extra protein and calories
Temperature control	Keep the baby warm from immediately after birth, by wrapping, using a hat and keeping the baby in an incubator, or under a warmer
Supportive care	Includes good positioning of the baby in an incubator or cot and the use of kangaroo care
Other: Minimise blood transfusions	Reduce blood sampling and the volume of blood taken. Blood transfusions have been linked with ROP

than 89% and not higher than 94% (the upper limit is 94% to prevent ROP). This means that the alarms on the monitors should be set at 88% and 95% so that they will sound if the oxygen saturation goes below or above this recommended range. Pulse oximeters are easy to use. They should be used for all preterm infants receiving supplemental oxygen. If there is not enough equipment to monitor oxygen levels in all babies, priority should be given to those who are unwell, those being handled, and those being given higher concentrations of supplemental oxygen.

Infection can be reduced by hand washing (or alcohol rubs after an initial wash) on entering the NICU and before and after handling each baby. This must be practiced by all. Measures to reduce skin breakdown, sterile techniques for intravenous lines, and careful use of antibiotics all reduce infection. Having an infection control team, headed by a senior nurse, is often beneficial.

Nutrition. Good nutrition and growth are essential for short- and long-term outcomes. There are many benefits of feeding preterm babies their own mother's breast milk, including lower rates of ROP. For babies below 1,000 g intravenous feeding may also be required.

Temperature control. Both high and low temperatures make babies unstable and can increase the need for oxygen. It can also worsen respiratory distress.

Supportive care practices are those which keep babies comfortable and stable, including kangaroo care and ensuring that babies' limbs are supported (pp. 53–54).

General aspects

In high-income countries, changes in how services for preterm infants are organised have improved the survival of preterm babies and reduced complications, including severe ROP. These include developing centres of excellence for the sickest preterm babies and better care of babies while they are being transported to or between neonatal units.

Providing better neonatal care requires team work between different health professionals (doctors, nurses, allied health workers) and working closely with parents and health authorities.

All units should have agreed protocols for important aspects of newborn care. These should be based on the best evidence available, i.e., from high quality clinical trials and systematic reviews. Good data collection methods are also needed in order to monitor trends and compare outcomes with similar neonatal units. Sharing information and best practices is easier if several units establish formal networks.

Making sure that preterm babies receive high quality care requires experienced nurses who do not have to look after too many babies. Ideally, one experienced neonatal nurse should not look after more than two sick infants. Working with parents is also very important (pp 60–61). There are many neonatal practices which can reduce the risk of severe ROP and so prevent blindness.

Further reading

Darlow BA, et al. Setting up and improving retinopathy of prematurity programs: interaction of neonatology, nursing and ophthalmology. *Clin Perinatol* 2013;40:215–27

Travers CP, et al. Exposure to any antenatal corticosteroids and outcomes in preterm infants by gestational age: prospective cohort study. *Brit Med J* 2017;356:1039

Lyu Y, et al. Association between admission temperature and mortality and major morbidity in preterm infants born at fewer than 33 weeks' gestation. *JAMA Pediatr* 2015;169:e150277

Ellsburly DL, et al. A multifaceted approach to improving outcomes in the NICU: the Pediatrix 100 000 babies campaign. *Pediatrics* 2016;137:e20150389

World Health Organization recommendations

World Health Organization. WHO recommendations on interventions to improve preterm birth outcomes. Geneva: World Health Organization, 2015, 98 pp. http://www.who.int/reproductivehealth/publications/maternal_perinatal_health/preterm-birth-highlights/en/

World Health Organization. Oxygen therapy for children. Geneva: World Health Organization, 2016, 57 pp. http://www.who.int/maternal_child_adolescent/documents/child-oxygen-therapy/en/

“Making sure preterm babies receive high quality care requires experienced nurses who do not have to look after too many babies.”

Preventing sight-threatening ROP: the role of nurses in reducing the risk



Ana Quiroga

Neonatology
Technical Advisor:
National Ministry of
Health and Director
of Postgraduate
Neonatal Nursing:
Austral University,
Buenos Aires,
Argentina.



Sarah Moxon

Research Fellow:
Maternal, Adolescent,
Reproductive and
Child Health
(MARCH) Centre,
London School of
Hygiene & Tropical
Medicine, London,
UK.

Neonatal nurses have frequent contact with preterm babies and their parents. By providing high quality care, nurses play an essential role in preventing retinopathy of prematurity.

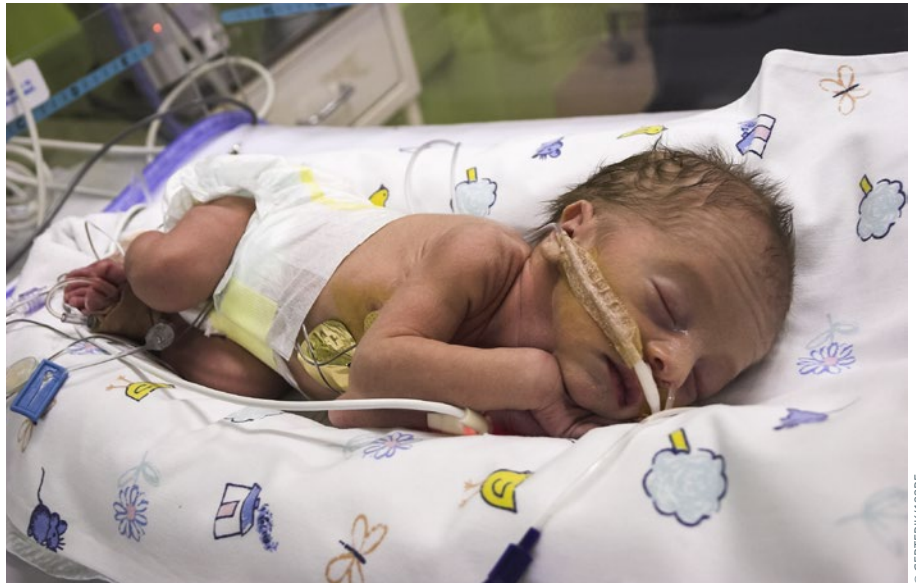

Figure 1 Positioning babies so they are comfortable and supported reduces stress and promotes normal neuromuscular development.

Skilled neonatal nurses play a central role as part of the multi-disciplinary neonatal team caring for preterm newborns. However, neonatal nursing is not a recognised profession in many countries, and nurses face significant challenges in providing high quality neonatal care.

Nurses can help to prevent ROP by focusing on reducing risk factors and through the day-to-day care they deliver. These are highlighted below using the POINTS of Care system (Figure 2).

Pain control

Procedures such as taking blood, setting up drips, or inserting a nasogastric tube are painful and can destabilise preterm babies. Painful procedures should be kept to a minimum, and pain can be reduced by giving the baby oral sucrose solution or a dummy (pacifier) to suck on before the procedure. For very painful procedures, systemic analgesics can be used.

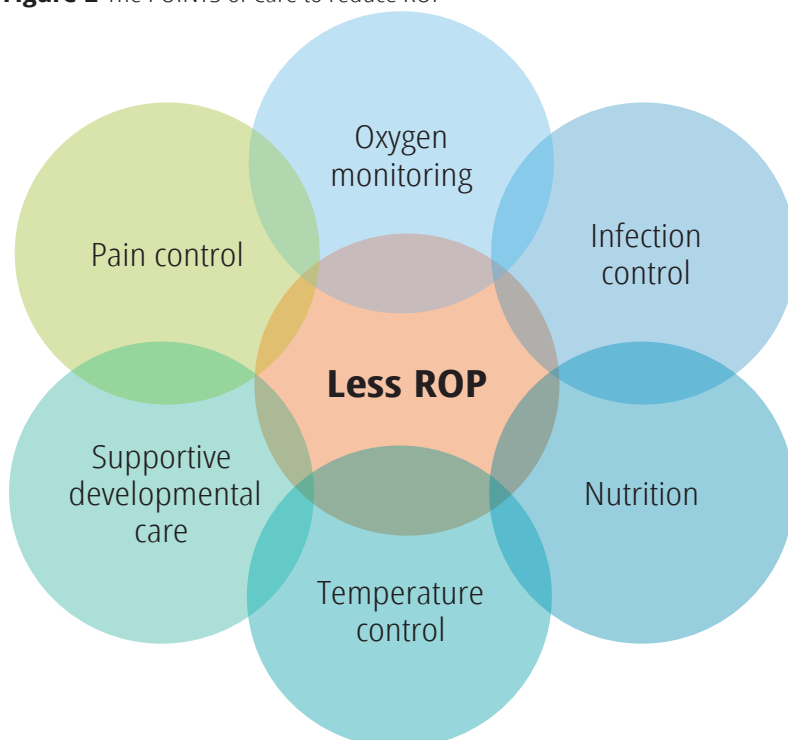
Oxygen monitoring

All nurses working in the neonatal unit are responsible for monitoring oxygen saturation using pulse oximeters, which is the standard of care for every newborn receiving supplemental oxygen (pp. 50–52). Nurses are responsible for ensuring that the concentration of oxygen is optimum by setting the alarms on oxygen monitors and responding quickly when they sound. Alarms must be set at 88% and 95% so that they sound if a baby's oxygen saturation falls below 89% or rises above 94%. Maintaining oxygen saturation within the targets recommended requires 24-hour care and a high level of awareness of the dangers of oxygen saturations that are too high or too low. Oxygen, compressed air, blenders, flowmeters, oxygen humidifiers, pulse oximeters, and monitors are essential items.

Infection control

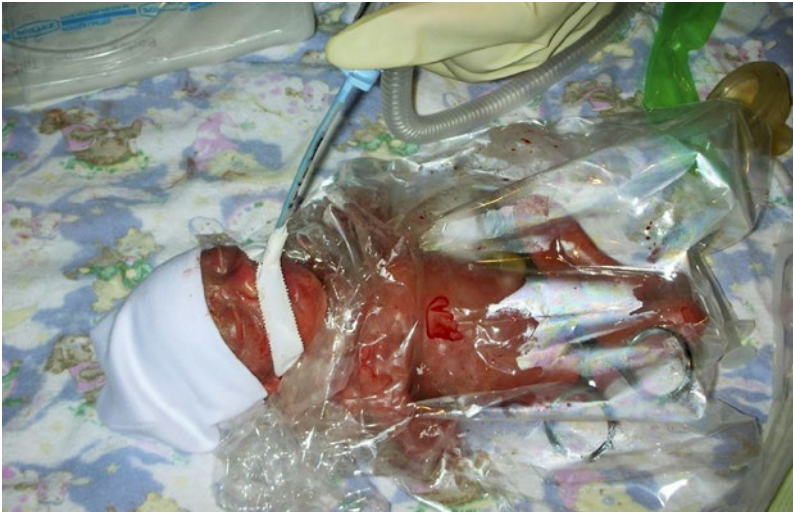Preterm babies are much more susceptible to infection than adults and are less able to combat it. Early-onset infection (within 48 hours of birth) is usually acquired during delivery. Late-onset infection is more common and is acquired through cross-infection within the neonatal unit. The key to preventing late-onset infection is hand washing on entering the unit and before and

Figure 2 The POINTS of Care to reduce ROP



Continues overleaf ➤

Figure 3 Placing a preterm baby in a plastic bag after birth is effective at maintaining normal body temperature



BRIAN DARLOW

after caring for every baby. This also applies to visitors and ophthalmologists. Other measures to prevent infection include careful skin preparation before taking blood or putting up a drip, ensuring that toys or other objects are not left in the cot, and avoiding the use of broad-spectrum antibiotics. Infection can also be reduced by keeping the neonatal unit clean and not sharing equipment, such as stethoscopes, between babies. Babies that are cared for by their mother and fed her breast milk have their gut colonised by helpful rather than harmful organisms.

Nutrition

Good nutrition is essential for the normal growth and development of preterm babies and helps to reduce the risk of infection and ROP. Preterm babies, like all other babies, need calories from fats and carbohydrates, protein, minerals and vitamins. The best food for preterm babies is their mother's own breast milk. If they are too immature to breast feed, breast milk can be given in very small amounts, within days of birth, using a small spoon, cup, or bottle. Mothers can express and store their milk in a refrigerator in the unit. Breast milk can be fortified with additional nutrients, or babies can be fed standard infant formula feeds. Intravenous nutrition is required for babies who are too immature or sick for oral feeding.

Temperature

Preterm babies are not able to shiver if they become cold. They compensate by consuming more oxygen, which increases their oxygen requirements. Nurses can control the surrounding environment by avoiding drafts, using incubators, or by using hats and warmed cots. Plastic bags can also be used (Figure 3). Kangaroo care (continuous and prolonged skin-to-skin contact with the mother or father – see p. 48), is a nurse-led intervention which helps preterm babies to maintain their temperature within the normal range.

Supportive developmental care

When preterm babies become stressed, their heart rate, respiratory rate and blood pressure all rise; this can lead to fluctuating oxygen saturations. Nursing care can reduce stress by reducing noise and bright lights

and by positioning babies so they are comfortable and their limbs are supported (Figure 1). Nurses can reduce the number of times they disturb babies by grouping procedures together and allowing longer periods when babies are pain free, comfortable and able to sleep. Kangaroo care also helps to keep babies stable and warm, increases maternal breast milk production, encourages breast feeding, and promotes bonding between parents and their child.

Avoiding blood transfusions and anaemia

Blood transfusion is a risk factor for ROP and unnecessary blood transfusions should be avoided. Anaemia in premature newborns is often exacerbated by taking too much blood for laboratory tests, too often. The smallest babies suffer the greatest proportional blood loss. Nurses are responsible for monitoring and limiting blood taking so that it is for critical tests only. When around 10% of total blood volume is used for blood tests, senior staff should be alerted.

Before and during screening

Neonatal nurses are responsible for preparing preterm babies for screening, preparing the equipment needed, and caring for the babies during screening. Dilating eye drops should be administered one hour before screening is due to ensure the pupils are well dilated. During screening, the infant should be wrapped securely and given sucrose solution or a pacifier to reduce pain. Nurses are experienced at positioning babies and can minimise head movement so that screening can be done as quickly as possible, particularly if the baby is unstable or sick. Nurses should also monitor the vital signs (heart rate, oxygen saturation, etc.) throughout the procedure and ensure that the baby is stable afterwards.

Challenges

Neonatal units in many low- and middle-income countries often have too few trained nurses. Many nurses have not had specialist training. Even in settings where nurses are trained, high staff turnover and rotation is common, leading to critical skills gaps and a lack of mentoring. Nurses cannot provide quality care if they do not have the right equipment and if there are no written policies and guidelines on safe oxygen use, for example. These factors disempower nurses and make it difficult for them to play a critical advocacy and leadership role in the planning, management, and day-to-day delivery of high quality neonatal care.

Summary

Nurses play a critically important role in preventing ROP. In countries where neonatal care is relatively new, nurses may not know about ROP nor appreciate how much they can do to prevent blindness from ROP in the babies they are caring for. As eye care professionals, we can educate them about ROP by adapting our teaching approach to match their levels of knowledge and experience.

Further reading

WHO; UNICEF. Every Newborn: An action plan to end preventable newborn deaths. Geneva: World Health Organisation 2014. Available from: http://www.healthynewbornnetwork.org/hnn-content/uploads/Every_Newborn_Action_Plan-ENGLISH_updated_July2014.pdf

Classifying retinopathy of prematurity



Andrea Molinari
Pediatric
Ophthalmologist:
Hospital
Metropolitano,
Av. Mariana de Jesus
Oe-8, Quito, Ecuador.



Dan Weaver
Pediatric
Ophthalmologist:
Billings Clinic,
Billings, Montana,
USA.



Subhadra Jalali
Director: Newborn
Eye Health Alliance,
(NEHA) and Director,
Quality: LV Prasad
Eye Institute,
Hyderabad, India.

Knowing how to classify retinopathy of prematurity is essential as it provides information on the prognosis and guides decision making about screening and treatment.

It is important to classify retinopathy of prematurity (ROP) in each eye, at each screening session. Doing so makes it possible to screen babies consistently and to make decisions about whether further screening is required and when, or whether laser treatment or surgical management is needed. The International Committee for the Classification of ROP¹ has classified it using the following criteria:

- 1 The severity of the ROP
- 2 The zone in the retina where ROP is found
- 3 The extent of the ROP
- 4 Whether the retinal blood vessels are dilated and/or tortuous (pre-plus or plus disease)
- 5 Whether aggressive posterior ROP is present

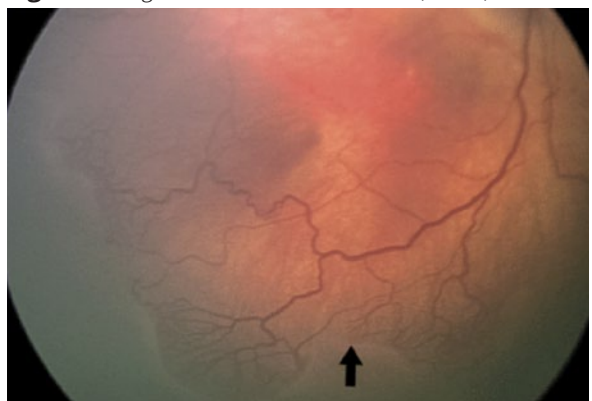
The severity of the ROP

ROP can develop when the immature retinal blood vessels have not reached the edge of the retina, known as the ora serrata.

- **Stage 1 ROP: Demarcation line.** A whitish line is visible between the normally vascularised retina and the peripheral retina in which there are no blood vessels (Figure 1)

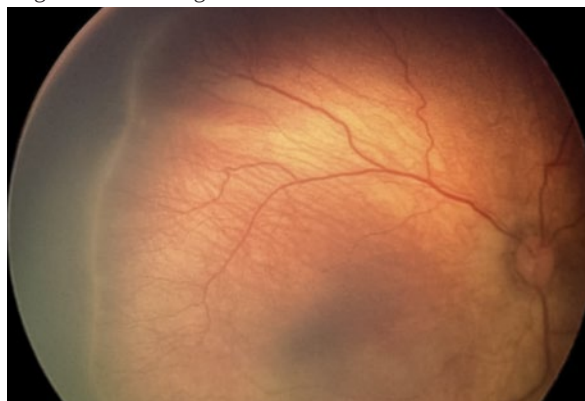
- **Stage 2 ROP: Visible ridge.** The demarcation line develops into a ridge, with height and width, between the vascular retina and peripheral retina (Figure 2).
- **Stage 3 ROP: Blood vessels in the ridge.** Blood vessels grow and multiply (proliferate) and are visible in the ridge (Figure 3).
- **Stage 4 ROP: Sub-total retinal detachment.** Vitreoretinal surgery may be indicated (Figure 4).
- **Stage 5 ROP: Total retinal detachment.** No treatment is usually possible (Figure 5).

Figure 1 Stage 1 ROP: Demarcation line (arrow)



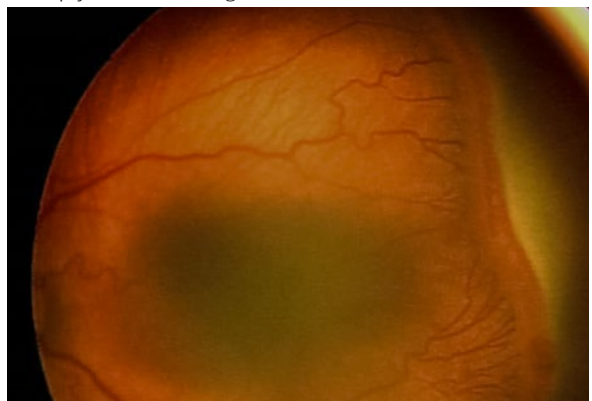
LYON DW AND WARREN DF. REVIEW OF OPTOMETRY 2006;14(3):12

Figure 2 Stage 2 ROP: The demarcation line becomes a ridge with both height and width



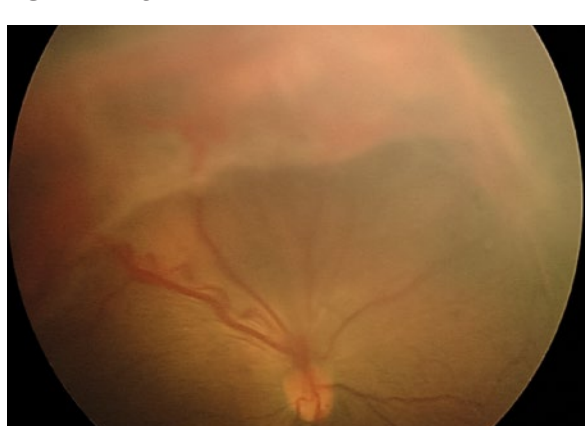BOOST-AZ

Figure 3 Stage 3 ROP: Abnormal blood vessels grow and multiply within the ridge



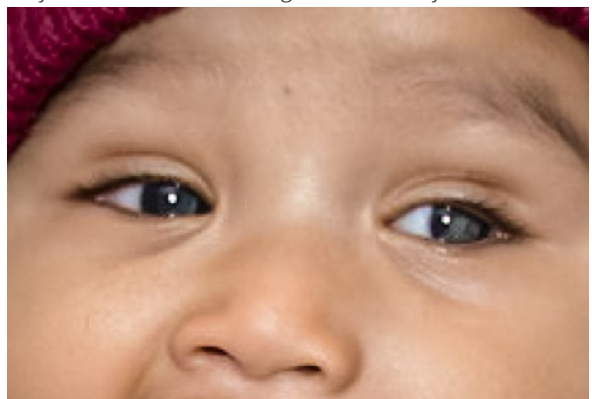DAI, AUKLAND DISTRICT HEALTH BOARD

Figure 4 Stage 4 ROP: Sub-total retinal detachment



ICEH

Figure 5 Stage 5 ROP: Total retinal detachment. Parents may notice this as something white in the eyes

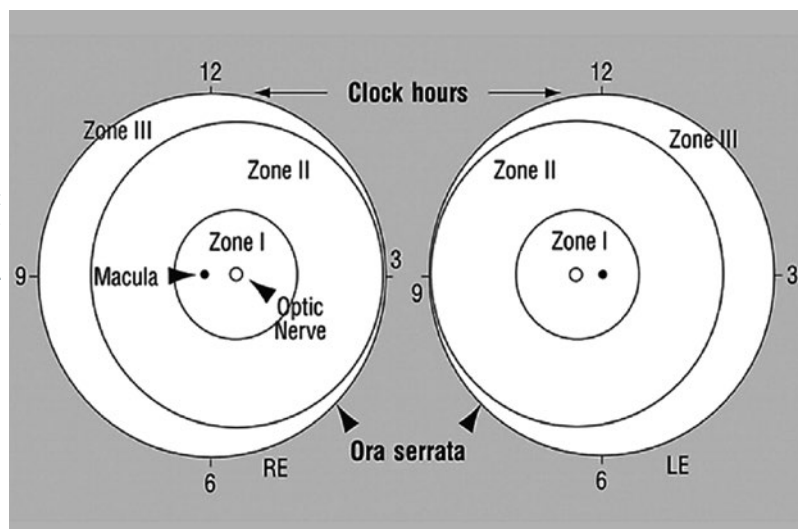


SUBHADRA JALALI

Reference

- 1 International Committee for the Classification of Retinopathy of Prematurity. The International Classification of Retinopathy of Prematurity revisited. Arch Ophthalmol. 2005;123(7): 991-9.

Figure 6 The three zones of ROP



The zones in the retina where ROP is found

The three zones of ROP are centred on the optic disc (Figure 6).

- Zone I is the small circle of retina around the optic disc. The radius of the circle is twice the distance from the macula to the centre of the optic disc
- Zone II is the ring-shaped section of the retina surrounding zone I, which extends to the ora serrata on the nasal side
- Zone III is a crescent-shaped area of temporal retina.

ROP in zone I is more likely to progress and become severe than ROP in zones II or III.

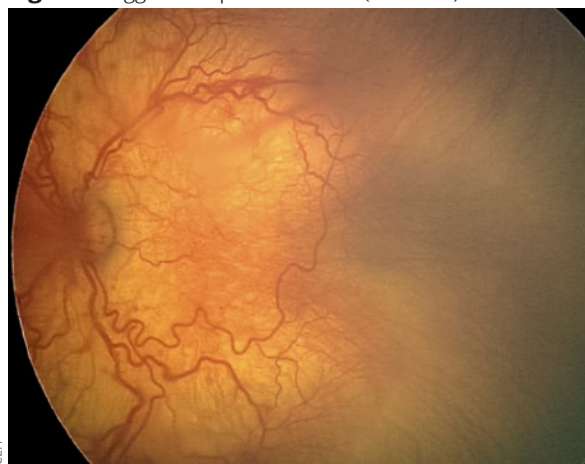
The extent of the ROP

The extent of disease is recorded as clock hours, in twelve 30° or 1-hour sections (Figure 6). The clock hours recorded are the total clock hours involved, not just the contiguous sectors.

The presence of plus disease

In plus disease, retinal arterioles and venules near the optic disc are dilated and tortuous. In pre-plus disease the changes are less pronounced, or may not affect all the blood vessels (Figure 7).

Figure 8 Aggressive posterior ROP (in zone I)



The presence of aggressive posterior ROP (AP-ROP)

Aggressive posterior ROP (AP-ROP) is nearly always in zone I. The proliferating blood vessels are flat and difficult to see, and plus disease is always present (Figure 8).

NOTE: It is very important to recognise AP-ROP as it can progress extremely quickly to retinal detachment. Treatment should be given within 48 hours.

How the classification can be used

Classification of ROP guides decision making about screening and treatment. For example:

- If immature retinal vessels are present, screening should be repeated
- If ROP is in zones II or III (further away from the optic disc) and is at stage 1 or 2, without any plus disease, the prognosis is good and the ROP is likely to resolve without treatment. Repeat screening is required in 1–2 weeks.
- If ROP is in zone I, or if it is Stage 3 with plus disease, or aggressive posterior ROP is present, urgent treatment is needed as the disease is very likely to progress to retinal detachment.

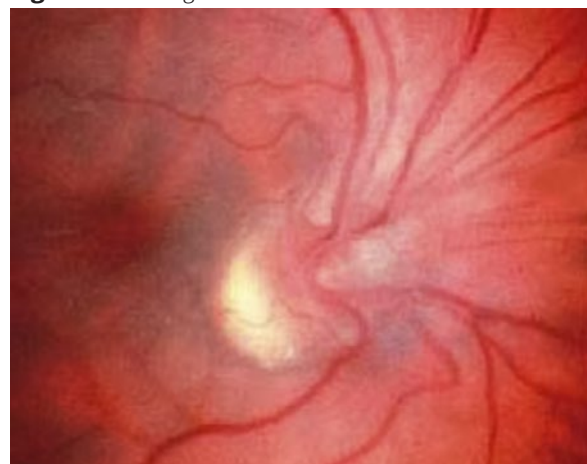
Scarring after ROP

Untreated ROP can sometimes heal with scarring in the peripheral retina and vitreous. This distorts the retina, leading to macular dragging or retinal folds. These signs are not included in the International Classification of ROP, but can be associated with loss of vision (Figure 9).

Figure 7 Plus disease: dilated and tortuous veins

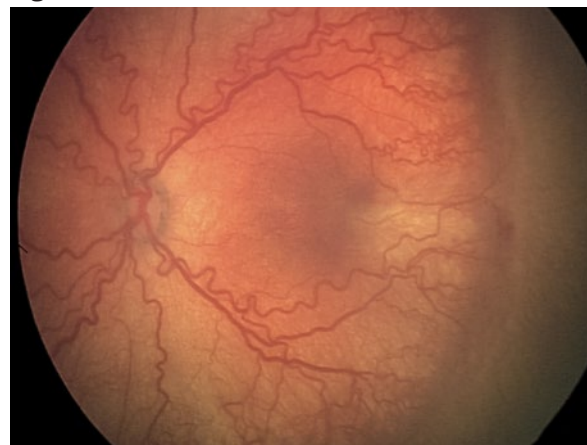

Figure 9 Scarring after ROP



Screening for ROP



Graham Quinn
Professor Emeritus
of Ophthalmology:
The Children's
Hospital of
Philadelphia,
Wood Center,
Philadelphia, USA.



Clare Gilbert
Professor of
International Eye
Health and
Co-director:
International Centre
for Eye Health,
London School of
Hygiene & Tropical
Medicine, London,
UK.

Screening babies for ROP is very important. Unless ROP is detected early and promptly treated, it can lead to blindness and permanent visual impairment. This article describes who to screen, when and where to screen, how to screen, and what to do next.

Why is screening needed?

Treatment for severe ROP is usually successful in preserving vision as long as treatment is given on time by an experienced ophthalmologist. The purpose of screening is to identify babies who need urgent treatment.

How and where should screening be done?

Most screening for ROP is undertaken by an ophthalmologist, using indirect ophthalmoscopy (Figure 1).

Babies who are in-patients in the neonatal unit must be screened in the unit. Babies who need further screening after discharge can be brought back to the unit for screening or they can be screened in the eye department.

Over the last few years, wide-field digital imaging systems, instead of indirect ophthalmoscopy, have also been used for screening. The retinal image can be captured by an ophthalmologist, a trained nurse, or a technician (Figure 2). However, an experienced

Figure 2 Screening using a RetCam, which uses a probe placed gently on the eye

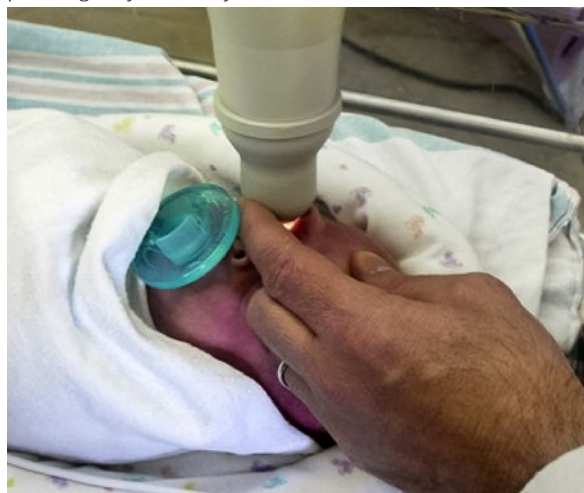


Figure 1 Ophthalmologist screening for ROP using indirect ophthalmoscopy

ophthalmologist must always be available to interpret the images.

The screening results for each eye must be classified according to the criteria set up by the International Committee for the Classification of ROP (see pp. 55–56).

Which babies should be screened?

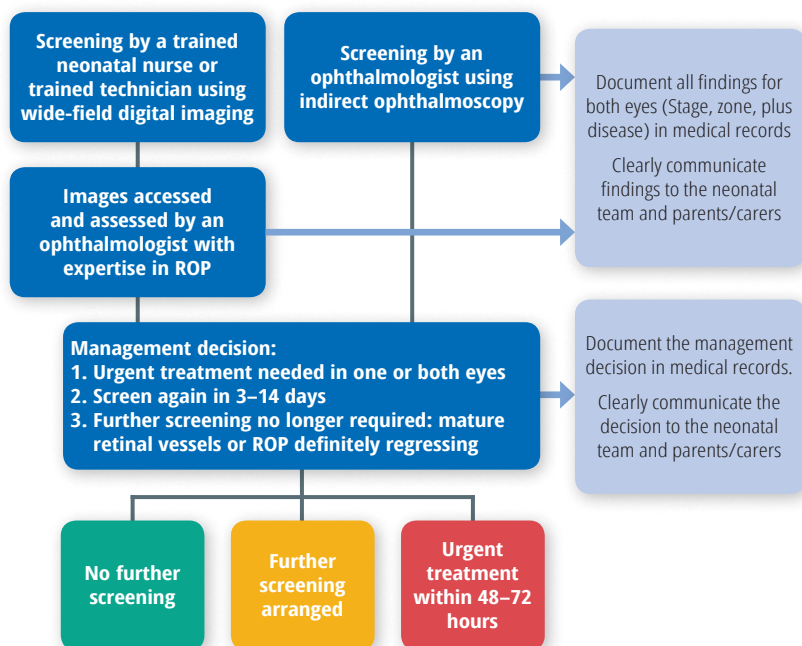
This is an important question. Which babies are at risk of severe ROP varies considerably. For example, in units where neonatal care is less than ideal, bigger, more mature babies can still develop severe ROP.

Several countries have national guidelines indicating which babies should be screened. These usually include a combination of birth weight (BW) and gestational age (GA). Some countries, such as the United States of America, include additional 'sickness criteria' alongside BW and GA. In neonatal units providing very high quality care, only the most preterm babies are at risk of developing ROP and therefore need to be screened.

- In the United Kingdom, babies with BW of <1,250 g, or a GA of 31 weeks or less, must be screened.
- In the United States of America, the screening criteria are a BW of 1,500 g or less, or a GA of 30 weeks or less. Infants with a BW between 1,500 g and 2,000 g should also be screened if they have had an 'unstable clinical course.'

Continues overleaf ➤

Figure 3 Screening options for ROP and the information to be documented and communicated



- In China, a middle-income country, the criteria are BW <2,000 g or GA <34 weeks. Compared with the UK and USA, older and bigger babies in China are considered to be at risk of developing ROP.

Ideally, studies need to be done in each country to determine which babies should be included in a screening programme.

Whichever criteria are used, it is the responsibility of the neonatologist to identify which babies should be screened, and a neonatal nurse should prepare the babies for screening (p. 54).

When screening should start

Preterm babies are not born with ROP; it only develops during the first few weeks after birth.

It is useful to have guidelines for the timing of the first screening which are easy to implement, particularly in settings where information on GA is unreliable.

For example, screen by 30 days of life. If the baby is very premature, or has been very sick or received a lot of oxygen, earlier screening should be considered. Current thinking suggests screening between 21 and 25 days of life, but more research is needed. If a baby eligible for screening is to be discharged or transferred to another neonatal unit before the first screening, they should be screened before discharge or transfer.

Understanding the findings of screening

- In eyes where the retinal blood vessels can only be seen in zone I at the first screening, about half will go on to develop ROP needing treatment.
- If the retinal blood vessels have reached zone II at the first screening, ROP needing treatment is unlikely.
- If mature vessels can be seen in zone III, ROP needing treatment is rare.

Making decisions

At each examination, a management decision needs to be made, based on the eye with the most advanced ROP (Figure 3).

The possible management decisions are:

- 1 Urgent treatment.
- 2 Further screening is needed (see below).
- 3 No further screening is needed as the retinal blood vessels are mature, or ROP is regressing in both eyes.

If urgent treatment is needed, this must be delivered within 48 to 72 hours. If further screening is needed, the date of the next screening examination must be documented and explained to parents. Figure 4 shows which babies need urgent treatment.

Repeat screening

Findings at the first examination determine when the next screening should take place.

- If the retinal vessels are immature and there is no ROP, follow-up screening can be conducted 1–2 weeks later.
- If there is Stage 1 ROP in zone II with no plus disease, repeat screening in 1 week.
- If there is Stage 2 ROP in zone II with plus disease, urgent treatment is needed.

Documenting and communicating findings and management decisions

It is very important that accurate records are kept for all babies who have been screened for ROP. This will help to ensure that babies are screened at the right time and that follow-up screening is done as and when needed. If a baby is not screened when they should have been, they are more likely to become visually impaired or blind. At each screening, document all findings for both eyes (immature retinal vessels, stage, zone, plus disease, aggressive posterior, ROP is regressing). Note whether treatment or further screening is needed, and when.

Finally, ensure that all information is shared with the neonatal team and the parents. ROP is a complex disease with long-term consequences and requires a team effort (see pp. 60–61).

Figure 4 Indications for urgent treatment from the Early Treatment of ROP Trial

		Stage 1	Stage 2	Stage 3
Zone I	No plus disease			
	With plus disease			
Zone II	No plus disease			
	With plus disease			
Zone III	No plus disease			
	With plus disease			
	Aggressive posterior ROP			

Repeat screening
 Urgent treatment (within 48–72 hours)

Treating ROP: how and when

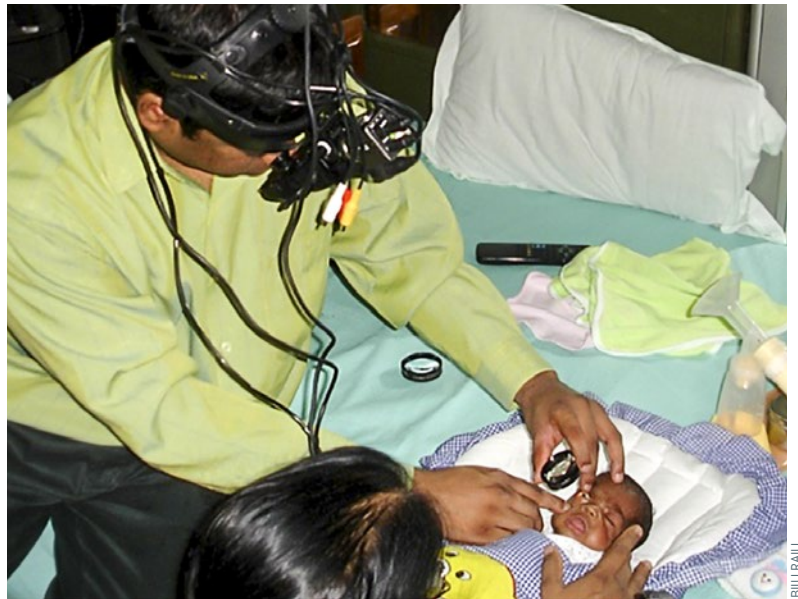

Graham Quinn
Professor Emeritus
of Ophthalmology:
The Children's
Hospital of
Philadelphia,
Wood Center,
Philadelphia, USA.



Clare Gilbert
Professor of
International Eye
Health and
Co-director:
International Centre
for Eye Health,
London School of
Hygiene & Tropical
Medicine, London,
UK.

Laser treatment of ROP is highly effective. However, special care should be taken when treating preterm or newborn infants, and long-term follow-up is essential. There are also new treatments on the horizon, particularly in cases where laser treatment is not possible or has failed.



Ophthalmologist checks whether ROP treatment has been successful. INDIA

Indications for treatment

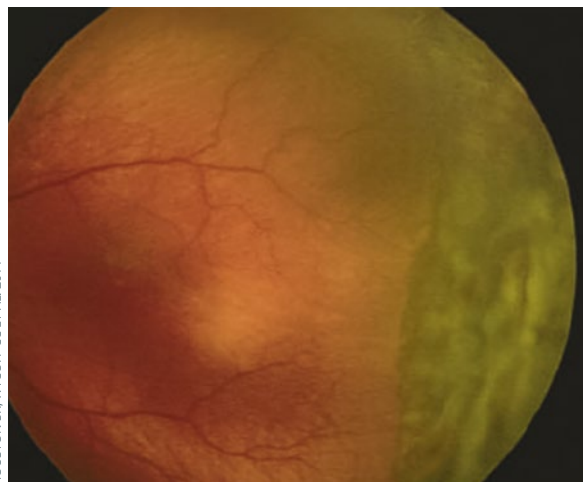
The Early Treatment of Retinopathy (ROP) trial (ET-ROP)¹ clearly showed that earlier laser treatment gives better results than waiting until 'threshold disease' develops. The ET-ROP indications for treatment use a combination of zone, stage and whether plus disease or aggressive posterior ROP is present (Figure 4, pp. 58).

ROP in zone I has the worst prognosis and so requires treatment at an earlier stage than ROP in zone II or III. The presence of plus disease also indicates a poorer prognosis. Eyes with plus disease and aggressive posterior ROP also have a poorer prognosis.

Laser treatment

The mainstay of treatment for severe ROP is peripheral retinal photocoagulation, delivered by laser. Only the avascular retinal periphery should be treated. The laser burns should be light and almost confluent (Figure 1). Laser treatment requires a trained and highly skilled ophthalmologist.

Figure 1 Photocoagulation pattern for ROP. The burns should be almost confluent.



HOUSTON SK, WYCOFF CC ET AL. 2011

Treatment is painful and should be given under topical anaesthesia with or without sedation, or under general anaesthesia. It is essential that the infant is monitored closely during treatment. A neonatologist or trained neonatal nurse must be present.

Babies should be followed up closely after treatment (after 1 week initially) to ensure that the ROP is regressing and that treatment of the peripheral retina is complete, with no skip areas (areas of untreated retina).

Further treatment should be given if the ROP is not regressing, including to skip areas.

Other treatment

Agents which block vascular endothelial growth factor (VEGF), which stimulates new vessel growth, are being explored as a treatment for ROP.² Although these agents, which are given by intravitreal injection, can give rapid short-term resolution of ROP, there are concerns about the long-term complications in the eye and possible systemic complications. For this reason, anti-VEGF agents are only recommended when laser treatment is not possible (i.e., the baby is too sick, the pupils do not dilate, or there is intravitreal haemorrhage) or when extensive laser treatment has failed. Parents should be fully informed about the risks before treatment and must give their consent.

Follow-up after treatment

All babies treated for ROP should have long-term follow-up visits to detect and manage the eye conditions which frequently develop in these children (pp. 62–64).

Reference

- 1 Good WV and the Early Treatment for Retinopathy of Prematurity Cooperative Group. Final results of the Early Treatment for Retinopathy of Prematurity (ETROP) randomized trial. *Trans Am Ophthalmol Soc.* 2004;102: 233-48.
- 2 Klufas MA, Chan RV. Intravitreal anti-VEGF therapy as a treatment for retinopathy of prematurity: what we know after 7 years. *J Pediatr Ophthalmol Strabismus.* 2015;52(2):77-84.



Involving the parents of preterm babies



Julie Flanagan

Retinopathy of Prematurity Screening Co-ordinator: Newborn Intensive Care Unit, St Marys Hospital, Central Manchester University Hospitals NHS Foundation Trust, Manchester, UK.



Erika Maka

Ophthalmologist and Paediatric Ophthalmologist: Semmelweis University, Maria Str. 39, Budapest, Hungary.



Cristina Nitulescu

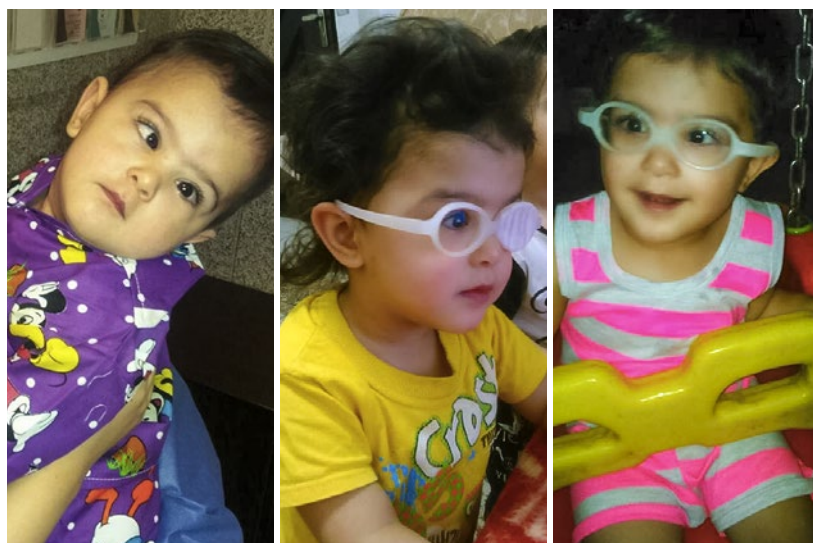Senior Ophthalmologist: Oftapro Ophthalmology Clinic and Institute for Mother and Child Health, Bucharest, Romania.

The prevention, detection and treatment of ROP is a team responsibility. Parents are important members of the team and their involvement is essential in ensuring optimal visual outcomes.

In the hospital, neonatologists, paediatricians, ophthalmologists, nurses and other allied health professionals are all involved in the care, screening and treatment of a baby with ROP. In such a busy clinical setting, it is easy to forget that parents are also important members of the team.

The role of parents must not be underestimated.¹ Not only can they help to prevent ROP in the clinic, they are also responsible for bringing their child back for screening and treatment appointments. Without parents' active involvement, ROP can have devastating consequences.

Good communication is at the centre of developing positive and productive relationships with parents, and it must start from the day a preterm infant is admitted to the neonatal unit. The members of the medical team can involve parents by communicating clearly and simply about the care their baby needs and how the parents can help. This builds a relationship of trust. It also helps parents to feel part of the team and to understand the important role they can play.



Thanks to excellent teamwork between parents and the medical team, a child with complications of ROP can now see well. **IRAN**

MAZANIN ZAHRA HOSEINPOUR

There are also practical things parents can do to help. Supportive care practices such as kangaroo care and feeding babies breast milk (pp. 50–54) not only improve health outcomes in preterm babies, but also involves the parents in a very positive way.

The parents' perspective

When the medical team's focus is on ensuring the survival of a preterm baby, it may be quite difficult to see the situation from a parent's perspective. Admission to a neonatal intensive care unit makes parenting very difficult: tubes, monitors and incubators can get in the way of the normal bonding between parent and child. Family-centred or family-integrated care (<http://familyintegratedcare.com>) is an approach that has been developed to enable parents to have the close interaction and contact they need with their infant¹; this also includes kangaroo care and feeding babies breast milk (from the breast or using a cup).

Supportive care practices and approaches can change the relationship between the medical team and parents by emphasising – to both parents and the team – the importance of working together. Many studies report significant improvement in clinical outcomes as a consequence of adopting these practices.^{2,3} Studies have shown that parents who are more aware of their child's medical condition, and who are engaged in their care while in the neonatal intensive care unit, have more positive attitudes and are more likely to bring their infant back for follow-up.^{4,5}

Educating parents and increasing their awareness about ROP should start weeks before the first screening appointment is planned. Parents need to be given time to absorb the information and to ask questions or express their concerns, and do so at their own pace. Nurses are ideally placed to start talking to parents about the potential complications of prematurity, including ROP and other visual complications (pp. 62–64). It is important to take into account the amount of information each parent wants at any specific time. Appointing an experienced nurse as an ROP co-ordinator can further enhance nurse-parent

The art of good communication

Parents of preterm infants are likely to be very anxious: they are in an unfamiliar environment and the health of their child can change rapidly. They may have other children or dependants at home and may not be able to spend much time in the neonatal unit. Parents often blame themselves for their child's condition and can feel helpless.

All our communication should be kind and understanding. Talk *with* parents and not *at* them. It is important to find out what they already know about prematurity, vision and the eye as this can provide the basis for communication. Simple, clear language is very important, so that what we say is understandable. Ask whether parents have any questions, and allow plenty of time for them to respond. Information may have to be repeated several times and may also change as the situation changes and the parents learn more, or are asked to do more.

Answering all questions without hesitation enhances parents' trust. We should let parents know that they can ask questions and can express their worries and concerns at any time. Empathy, listening and patience are essential in good communication, as is good eye contact. Wait until a parent has finished before you reply; interrupting can prevent parents from asking important questions or sharing important information with the medical team. Parents like to know the simple truth.

communication.⁶ When it is time for ROP screening, a nurse or neonatologist who knows the parents well can introduce the ophthalmologist, as this builds trust.

For many infants, ROP screening starts in the neonatal unit but continues after they have been sent home with their parents. Parents need to understand the importance and the timing of screening so that they will bring their child back at the right time. They also need to know that laser treatment, if needed, cannot be delayed. Infants who have had treatment need regular follow-up visits to ensure that the treatment has been successful in the short term, and to detect and manage complications in the longer term (pp. 62–64). The active engagement of parents can, therefore, make all the difference between success and failure in preserving their child's vision.

Supporting communication

Written and visual materials can help to support verbal communication. Posters which use simple language and clear images can be used to explain the importance of ROP screening, and that treatment may be needed. (Note: The images in this issue can be used for posters and other educational materials, except if there is a copyright notice. Visit www.flickr.com/communityeyehealth to download high-resolution images.)

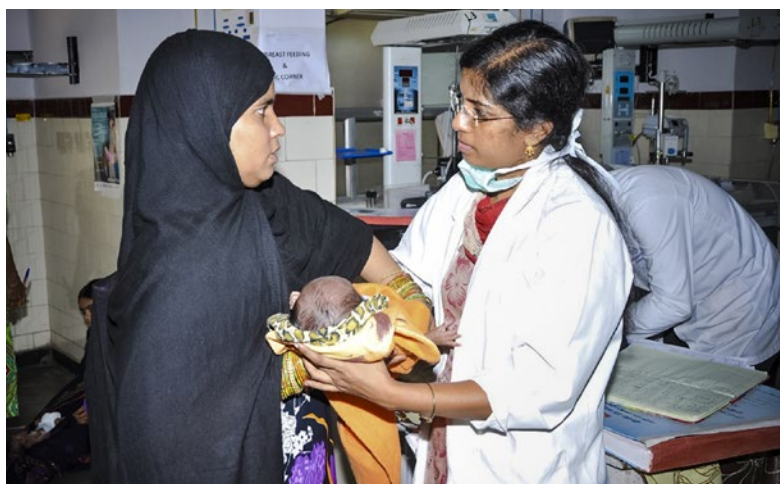If parents are given a booklet when their baby is admitted, ensure that ROP is mentioned. This provides a gradual introduction to ROP in the first few days after admission.

Each unit should have a parent information booklet about ROP which parents can read themselves and which staff can use as the basis of education and counselling. The booklet should use simple terminology and provide consistent information which the team can refer back to if required. Highlight the fact that the risk of ROP can be reduced and that treatment (if needed) is usually successful.

Cover the following topics:

- What is ROP and why does it occur?
- How common is ROP?
- How is ROP detected?
- What should we expect during and after an eye examination?
- Will my child need treatment?
- What happens if my baby is unwell?
- Where can I find out more? (with websites if appropriate)
- Contact details for members of the neonatal team or the ophthalmologist

Figure 1 An ophthalmologist explains to the mother the importance of screening a preterm baby.



Images of the normal retina and the retina with ROP can be a very useful way to educate parents about ROP.

Systems to support parental involvement

The ophthalmologist is the best person to communicate the findings of screening to parents, accompanied by a member of neonatal team whom the parents already know (usually a nurse). The ophthalmologist should explain what the findings mean using clear, non-technical language (Figure 1). The nurse can provide additional information if the parents have questions or concerns after the ophthalmologist has left the unit.

Maintaining good medical records of the findings of screening, the management decision, and any follow-up (see p. 58), is essential. Note whether parents were informed personally about the findings and what happens next. Good medical records also enhance team communication. The consultant neonatologist or paediatrician is responsible for co-ordinating follow-up screening, either in the neonatal unit or the eye department after discharge. This responsibility can be delegated to the ROP nurse co-ordinator, if one is in post, or a nurse.

If a baby is to be discharged from the unit before ROP screening has been completed, it is crucial that the first follow-up appointment is made before the family leaves. The neonatal team must have the correct contact details for the family, i.e., their address and two up-to-date mobile numbers, so that they can be reminded about about the next appointment and contacted immediately if they do not attend for screening or treatment.

Give parents the following information:

- The appointment date, time and place (which may be in the unit or in the hospital where the ophthalmologist works)
- Who to contact if there are problems
- Details about transport assistance or reimbursement of costs for travel, if appropriate
- Information about the consequences of late screening and the potential risk of blindness if screening does not take place.

This must be written in the child's medical records and in the discharge summary (which the parents keep).

In conclusion, good communication is an art which can be improved. It supports parental involvement, which in turn contributes to good medical care and better outcomes for a baby with ROP.

References

- 1 Ho LY, Faia LJ and Trese MT. Safety Net for ROP Management. *Expert Review of Ophthalmol.* 2014;327–331.
- 2 Wigert H, Blom M, Bry K. Parental experiences of communication with neonatal intensive-care unit staff: an interview study. *BMC Pediatr* 2014;14: 304.
- 3 O'Brien K, Bracht M, Macdonell K et al. A pilot cohort analytic study of Family Integrated Care in a Canadian neonatal intensive care unit. *BMC Pregnancy and Childbirth* 2013; 13(Suppl 1): S12.
- 4 Vinekar A, Jayadev C, et al. Improving follow-up of infants during retinopathy of prematurity screening in rural areas. *Ind. Paed.* 2016(53): S151–S154.
- 5 Mousavi SZ, Karkhaneh R, Roohipour R, et al. Screening for retinopathy of prematurity: the role of educating the parents, *Iran J Ophthalmol* 2010; 22(2):13–18.
- 6 Coats, DK and Reddy, AK (2009). *Retinopathy of prematurity. In: Pediatric Ophthalmology: Current Thought and A Practical Guide* (pp. 375–386). Springer Berlin Heidelberg.

Following up children born preterm



P Vijayalakshmi
Chief, Paediatric
Ophthalmology &
Strabismus, Aravind
Eye Care System,
Madurai, Tamil
Nadu, India.



Clare Gilbert
Professor of
International Eye
Health and
Co-director:
International Centre
for Eye Health,
London School of
Hygiene & Tropical
Medicine, London,
UK.

Babies born preterm, particularly those who have been treated for retinopathy of prematurity, are at greater risk of other eye conditions. Examining these children again, at the right time, can save their sight.

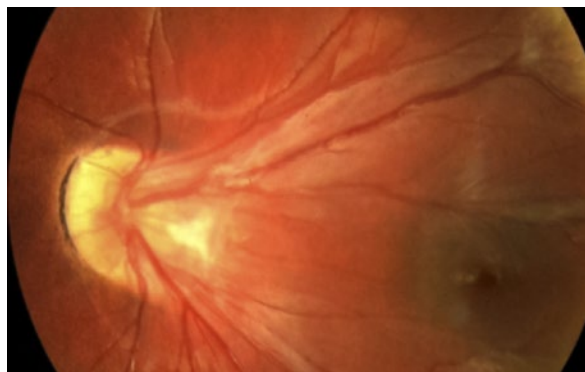


A six-year-old girl with stage 5 ROP in her right eye. Her left eye can see 6/60 after vitrectomy for stage 4b ROP and cataract surgery. INDIA

Preterm babies, and newborns who are unwell, are now surviving at higher rates globally than ever before. This is the result of expansion and improvement in services for sick and preterm babies. However, preterm birth is associated with a range of complications, including retinopathy of prematurity (ROP), and preterm infants are at a far higher risk of disabilities – including blindness – than healthy, full-term babies.¹ Clinicians, together with low vision and rehabilitation specialists, can play a key role in reducing visual impairment and promoting normal development in this group of children.

The most common visual complications of prematurity are ROP and cerebral visual impairment (CVI), secondary to brain damage. CVI is associated with developmental delay and cerebral palsy. All preterm babies are at increased risk of refractive errors, particularly myopia, astigmatism, anisometropia (different refractive errors in each eye), and strabismus.^{2,3} All of these conditions increase with increasing prematurity. Some babies, particularly those who have been treated for ROP with laser, can develop cataract and glaucoma. The consequences of ROP can also lead to scarring and distortion of the retina, with loss of vision (Figure 1).

Figure 1 Scarring and distortion of the retina is one of the consequences of ROP.



Refractive errors

In children who were born preterm, refractive errors have an early age of onset. It is important that any refractive errors are detected and managed properly in order to prevent amblyopia. However, it is important to bear in mind that the refractive status of the eyes changes dramatically over the first few years of life as the eyes grow, with most children's eyes becoming emmetropic (no refractive error) by the time they are 5–6 years old. It is thought that peripheral laser treatment for ROP, or the ROP itself, may interfere with these processes, leading to refractive errors.

Myopia

Preterm babies are more likely to develop myopia than full term babies, even if they did not develop ROP. This is usually relatively low myopia, which develops at around the age of 4–5 years (the blue line in Figure 2). Babies who have developed any degree of ROP are at a higher risk than those who did not, and the myopia may be more severe and have an earlier onset (green line). Babies who have been treated for ROP using laser are at greatest risk, and may develop high myopia within a few months of treatment (orange line). Their myopia can progress rapidly before it stabilises (Figure 2).

Figure 2 The risk and age of onset of myopia in children born preterm, depending on whether they developed ROP and whether they were treated for it

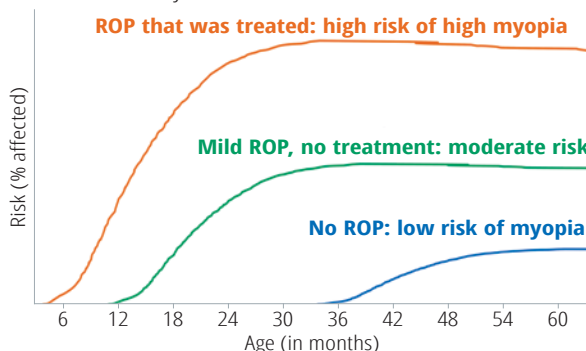


Table 1 Ocular complications of preterm birth and suggested timing of first examination

Preterm baby with ...	What to look for	Level of risk	Timing of first and subsequent examinations
No ROP	Myopia	Low	At 2 years of age and annually thereafter
ROP, but no laser treatment needed	Myopia, astigmatism, strabismus	Moderate	At 1 year of age and annually thereafter
ROP, treated with laser	High myopia, astigmatism, strabismus, CVI, anisometropia	High	At 3 months of age and every 3–4 months to 2 years of age; then every 6 months to 6 years; and annually thereafter

Astigmatism due to anisometropia

Astigmatism (due to an irregularly shaped cornea) and anisometropia are common, particularly following ROP treatment. Both can lead to amblyopia, which can be bilateral, if not detected and treated early. Treatment involves spectacle correction and daily intermittent occlusion of the better-seeing eye, with frequent follow-up visits.

Strabismus

Strabismus (squint) is less common than refractive errors and may occur either in isolation or with a refractive error. Children with cerebral palsy following preterm birth are more likely to have strabismus. The degree of misalignment can vary over time, making the decision whether and when to operate more difficult than in children who were born at term.³

Cerebral visual impairment and other eye conditions

Cerebral visual impairment should be suspected if the parents report that their child does not seem to see normally in the absence of any obvious ocular cause (although optic atrophy often accompanies CVI).

Cataract and glaucoma can develop either spontaneously or following treatment for ROP. The management

of cataract and glaucoma in infants born preterm is extremely challenging, with glaucoma having a poor prognosis.

Assessing and following up young children born preterm

It is recommended that all children who were born preterm are assessed by an ophthalmologist, particularly children who were treated for ROP and those with mild ROP which did not require treatment. However, there are no agreed guidelines for when this should be done. Table 1 gives some suggestions. At both initial and follow-up visits, consider the following:

- Is the child developing normally?
- Does the child seem to have normal vision?
- Is strabismus or nystagmus present?
- Does the retina look normal/healthy?
- Is there a significant refractive error?
- Are there any other eye problems, such as cataract?

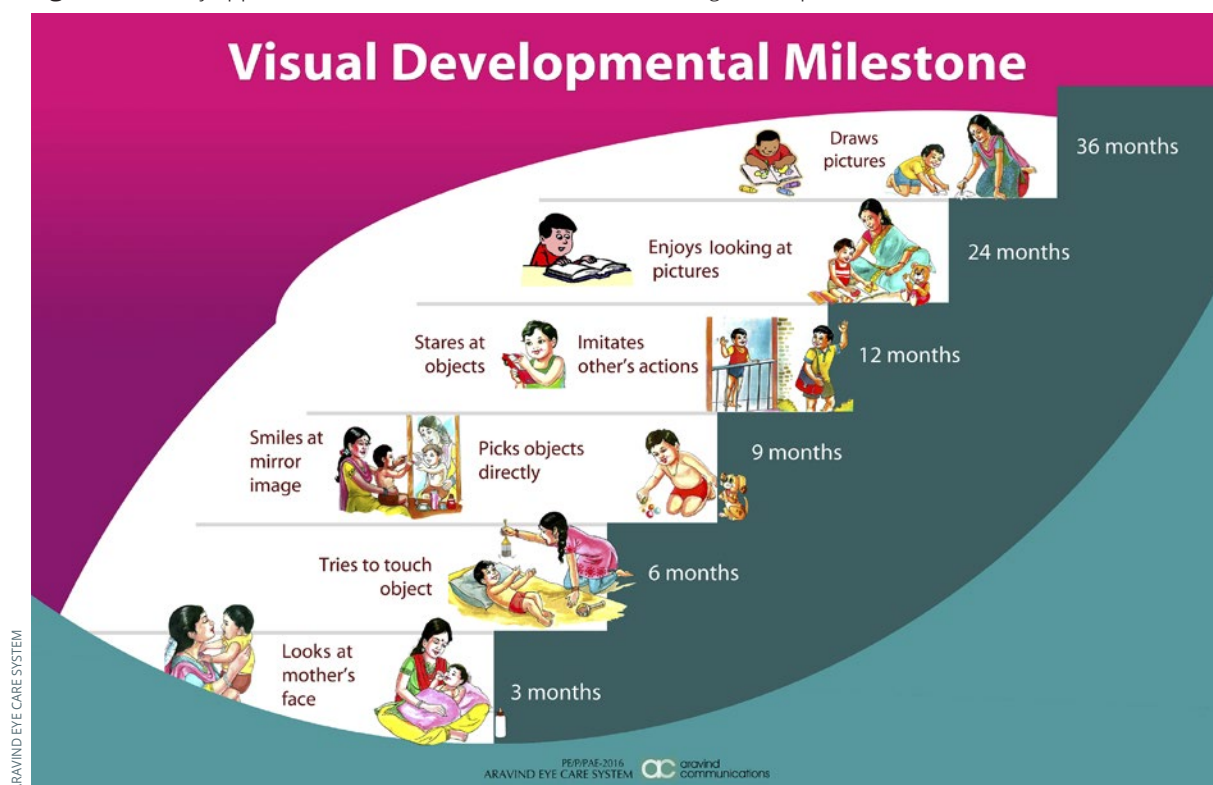
Many parents believe that children born preterm develop more slowly than babies born at term. This is not the case in uncomplicated prematurity, and so it is important to assess the child's overall development (Table 2). Children born preterm are more likely to have

Continues overleaf ►

Table 2 Developmental milestones for children aged three months to 5 years

3 months	7 months	1 year	2 years	3 years	4 years	5 years
Begins to develop a social smile	Enjoys social play	Enjoys initiating play with others	Walks alone	Climbs well	Goes upstairs and downstairs without support	Swings, climbs, hops and somersaults
Raises head and chest when lying on the stomach	Transfers objects from hand to hand	Reaches sitting position without assistance	Points to objects or pictures when they are named	Turns book pages one at a time	Draws circles and squares	Says name and address
Watches faces intently	Ability to track moving objects improves	Bangs two objects together	Begins make-believe play	Uses 4 to 5 word sentences	Tells stories	Can count 10 or more objects
Smiles at the sound of your voice	Responds to own name	Responds to simple verbal requests	Demonstrates increasing independence	Sorts objects by shape and colour	Co-operates with other children	Likes to sing and dance
	Finds partially hidden objects					

Figure 3 At every appointment, check whether children are achieving their expected visual milestones



global developmental delay (i.e., affecting all aspects of motor, social and cognitive development), or cerebral palsy, cognitive disability or autism. These children need to be identified early and referred for specialist care, for example to a developmental paediatrician or physiotherapist.

Measuring visual acuity in young children is extremely difficult, but their visual functioning can be assessed using visual development milestones (Figure 3). Children who are irreversibly visually impaired or blind should be referred for vision rehabilitation.

Ocular alignment and eye movements should be assessed, and dilated examination of the retina and optic disc should be performed. Measure IOP and axial length when needed.

NOTE: Refraction should be performed with cycloplegia. If refraction is unreliable, consider refraction with atropine cycloplegia, under general anaesthesia.

Prescribing and dispensing spectacles for young children

As a young child's visual world is near, it is not necessary to prescribe for, or fully correct, all simple myopia.

Suggestions for prescribing at different ages are shown in Table 3, which should be tailored to the individual child.

Young children do not have a well-formed bridge to their nose, and they require small frames and accurate centration of the lenses. The arms of the frame should fit around the ears, or the arms can be tied behind the child's head. Light, plastic lenses should be used.

Counselling parents

Parents may be shocked and upset when they hear that their small child needs to wear spectacles or needs occlusion. This is particularly true for parents of babies who have been treated for ROP as they will already have had many anxieties and hurdles to overcome. Careful and repeated counselling is required to ensure that parents fully understand the need for their child to wear spectacles, that frequent follow-up will be required and the spectacles may need to be replaced.

Summary

Children born preterm can have a range of complications which can impact on their development and the rest of their life. Successful management and the best possible outcome depends upon recognising and treating any problems as early as possible.

References

- 1 Beligere N, Perumalswamy V, Tandon M, Mittal A, Floora J, Vijayakumar B, Miller MT. Retinopathy of prematurity and neurodevelopmental disabilities in premature infants. *Semin Fetal Neonatal Med.* 2015 Oct;20(5):346–53.
- 2 Fielder A et al. Impact of retinopathy of prematurity on ocular structures and visual functions. *Arch Dis Child Fetal Neonatal Ed.* 2014;0:F1–F6.
- 3 Vijayalakshmi P., Kara T. and Gilbert C. Ocular Morbidity Associated With Retinopathy of Prematurity in Treated and Untreated Eyes: A Review of the Literature and Data From a Tertiary Eye-care Center in Southern India. *Indian Peds* 2016 53: Supplement 2:137–142.

Table 3 Prescribing guidelines for young children born preterm

	3–18 months	18 months onwards
Prescribe if ...	Sphere more than $\pm 5D$ and/or Cylinder $\geq 2.5D$ and/or Anisometropia $>1.5D$	Sphere more than $\pm 3D$ and/or Cylinder $\geq 2.5D$ and/or Anisometropia $>1.5D$
Prescribe on an individual basis if ...	Sphere less than $\pm 5D$ and Cylinder less than $2.5D$ and Anisometropia less than $1.5D$	The refractive error is the same on two consecutive visits, two months apart

Reaching remote Amazonian communities to eliminate trachoma



Julian Trujillo Trujillo

Group Coordinator for the Integral Management of Emerging, Re-emerging and Neglected Diseases: Ministry of Health and Social Protection of Colombia.



Tim Jesudason

Communications Specialist: International Coalition for Trachoma Control, London, UK.



Girija Sankar

Assistant Director of Programs & Communications: International Trachoma Initiative Atlanta, USA.

Worldwide, many indigenous peoples are at risk of developing trachoma, a bacterial eye disease that disproportionately affects the world's poorest communities. In Colombia's remote Amazonian districts, trachoma is still endemic amongst many of the indigenous communities that live there.

The remoteness of these communities often means they have limited access to formal health care services, which makes trachoma elimination very challenging. However, extraordinary new efforts by Colombian health authorities to tackle trachoma have shown that great progress can be made if there are adequate resources, co-ordination and local engagement.

Maximising efficiency

From 2012–2016, the Colombian Ministry of Health researched and created maps showing where trachoma was most prevalent in its Amazonian districts. This was needed to identify all people at risk of trachoma, and to understand where resources had to be allocated. Reaching indigenous communities in the Amazonian districts presented major logistical challenges and required substantial resources due to the contrasting landscapes and limited travel routes. Sometimes, flights had to be chartered; at other times, boats had to be carried along trails where rapids or waterfalls interrupted river travel routes.

Once the mapping work was complete and the Government understood the scale of the trachoma burden, the next challenge was to figure out the best way to deliver treatment in these hard-to-reach areas. To maximise efficiency, program managers developed an 'integrated package' of interventions. Alongside the distribution of antibiotics for trachoma, health workers also distributed treatments for soil-transmitted helminths. Because under-developed areas are frequently burdened by a number of diseases that thrive in areas with poor access to clean water and sanitation, Colombian health authorities also established intercultural dialogue to educate the communities about the relationship between personal hygiene and good health. This integrated approach delivered treatment and education to over 400 Amazonian communities, significantly improving health in these communities while maximising the impact of resources.

Tailored programming

Innovative programming approaches were needed in order to deal with the great cultural diversity among the indigenous communities. Community structures, languages, levels of education, migration patterns, environmental conditions and attitudes to health interventions all differed vastly from village to village, and programme staff encountered over 50 different languages throughout the region. Many indigenous communities also live semi-nomadic lifestyles and



Community members being checked for trachoma in Mitu, Vaupés District. COLOMBIA

JULIAN TRUJILLO TRUJILLO

frequently cross international borders, making prevention, treatment and surveillance programmes difficult to implement and maintain.

In order to tackle these challenges, health workers from the same or nearby districts were recruited and trained, wherever possible. This helped programme staff to gain a better understanding of local cultures and any migration patterns that might affect planned health care programmes. The health workers could also readily translate information into the local language, which increased trust between programme staff and community leaders, thereby increasing community confidence in programme interventions.

Colombian health authorities are also developing working relationships with neighbouring countries and their health authorities in order to overcome the challenges posed by migration. National programme managers meet regularly to discuss trachoma elimination strategies at major events such as the World Health Organization (WHO) Pan-American Health Organization regional meeting, where experiences are shared and relevant courses of action are decided. This regional collaboration has had a positive impact on cross-border interventions and has led to new initiatives, including mapping for trachoma and soil-transmitted helminths in Peru along the Amazonian basin, near the border with Brazil and Colombia.

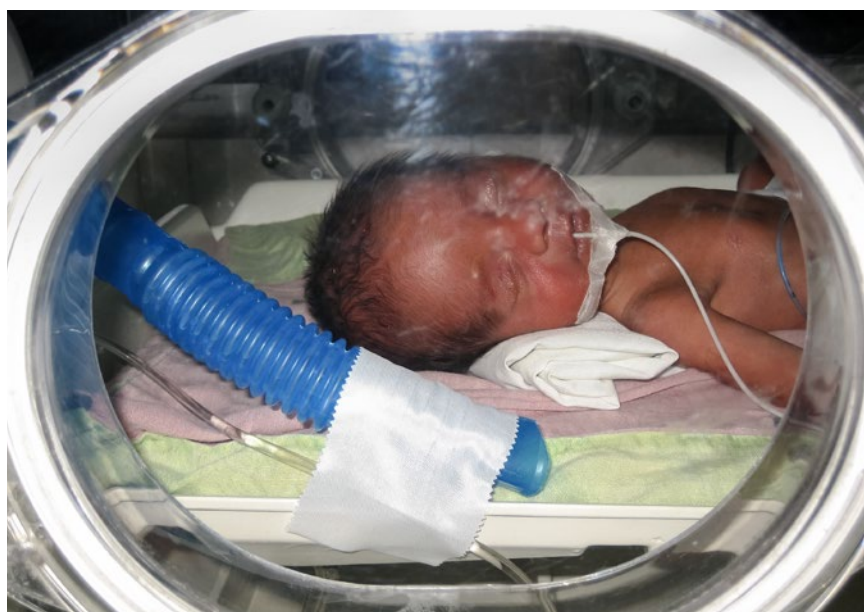Going forward

Despite recent progress, Colombia has more to do in order to eliminate trachoma as a public health problem by 2020. Around 180,000 people are still at risk of trachoma in remote and hard-to-reach parts of the country. The good news is that Colombia's experience shows that tailoring programmes to fit the needs of indigenous people works. With adequate resources, extensive context-specific planning, extended timeframes and strong consultation with a range of stakeholders, from village chiefs to foreign health departments, programmes can improve health among indigenous communities.



Test your knowledge and understanding

This page is designed to help you to test your own understanding of the concepts covered in this issue, and to reflect on what you have learnt.



CLARE GILBERT

Preterm baby being given unmonitored supplemental oxygen (via the blue tube). The baby is very pink and hyper-oxygenated. This increases the risk of ROP and must be avoided.

We hope that you will also discuss the questions with your colleagues and other members of the eye care team, perhaps in a journal club. To complete the activities online – and get instant feedback – please visit www.cehjournal.org

Tick ALL that are TRUE

Question 1

Which of the following factors can increase the risk of for ROP during the first 4 weeks of life?

- ☐ a Infection
- ☐ b Poor weight gain after birth
- ☐ c Oxygen saturations that are above 95%
- ☐ d Gestational age of 36 weeks or above
- ☐ e Low body temperature

Question 3

Treatment of ROP

- ☐ a Laser treatment is painful
- ☐ b ROP in zone 3 has a worse prognosis than ROP in zone 1
- ☐ c The laser spots should be confluent
- ☐ d Stage 2 ROP in zone 2 with plus disease should be treated
- ☐ e After treatment, babies should be seen again in 4 weeks

Question 2

Screening for retinopathy of prematurity

- ☐ a The ophthalmologist should identify which babies should be screened
- ☐ b The first screening should take place as soon as the neonatologist says the baby is well enough
- ☐ c An ophthalmologist should visit the unit every two weeks to screen
- ☐ d Babies with plus disease should be screened again in a week
- ☐ e Screening is usually undertaken using an indirect ophthalmoscope

Question 4

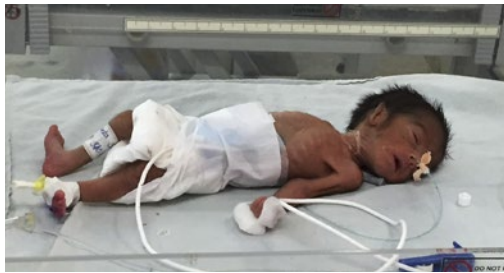Follow-up of babies who developed ROP

- ☐ a Babies who have been treated for ROP have more complications than babies who had ROP that did not need treatment
- ☐ b Strabismus should be operated on as soon as it is detected
- ☐ c High myopia can occur within a few months of laser treatment
- ☐ d Occlusion therapy may be required to prevent or treat amblyopia
- ☐ e Children born preterm may be developmentally delayed

ANSWERS

1. a, b, c and e are true. Gestational age of less than 36 weeks is a risk factor.
2. a, c, and d are true. Zone 1 ROP has a worse prognosis, and babies should be seen within 1–2 weeks of laser to ensure that the disease is regressing.
3. e is true. The neonatologist should identify which babies need to be screened, and screening must be done before 30 days after birth. An ophthalmologist should visit the unit once a week, and all babies with plus disease require treatment.
4. a, c, d, e are true. In children with strabismus who were born preterm, the degree of misalignment can vary so the decision about when to operate is more difficult.

Picture quiz



CLARE GILBERT

Tick ALL that are TRUE

Question 1 What could be done to improve the care of this preterm baby?

- ☐ a Monitor blood oxygen saturation
- ☐ b Kangaroo care
- ☐ c Feed the baby with the mother's breast milk
- ☐ d Support the baby's limbs
- ☐ e Keep the baby cool

Question 2 How is ROP classified?

- ☐ a Aggressive posterior ROP
- ☐ b 5 zones
- ☐ c 5 stages
- ☐ d Posterior ROP
- ☐ e 3 zones

Question 3 Screening for ROP

- ☐ a Can be done at any time as long as the baby is stable
- ☐ b Can cause the baby stress
- ☐ c Is never needed after the baby is discharged from the neonatal unit
- ☐ d Should include babies at risk even if they are sick
- ☐ e Should be done by 30 days after birth

Question 4 Follow-up of children born preterm

- ☐ a Refractive errors are uncommon after laser treatment for ROP
- ☐ b Babies less than 12 months of age should not be given spectacles
- ☐ c Some preterm babies are developmentally delayed
- ☐ d A normal eye examination means the child can see normally
- ☐ e Strabismus is easy to manage

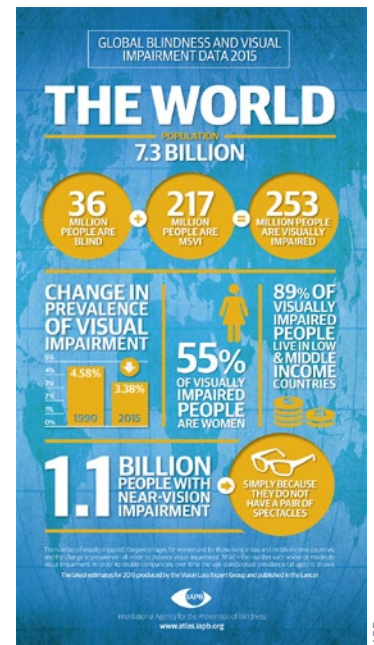
ANSWERS

1. a, b, c and d are true. Premature babies need to be kept warm; a plastic bag can be used immediately after birth (see p. 54).
2. a, c and e are true.
3. b, d and e are true. Babies who are premature or low birthweight should ideally be screened by 30 days of life.
4. c is true. After laser treatment, a high degree of myopia can develop within a few months of treatment, while they are still infants (<12 months of age). Low degrees of myopia do not need to be treated immediately; but high myopia should be treated to prevent amblyopia. Strabismus can be difficult to manage because it can change over time.

ANNOUNCEMENTS & RESOURCES

IAPB Vision Atlas

The IAPB Vision Atlas was launched on World Sight Day 2017. It contains the latest data on prevalence and causes of blindness and visual impairment by region and country, as well as projections to 2020 and 2050. It also includes the success indicators (e.g., cataract surgical coverage, number of eye health personnel) needed to achieve the WHO Global Action Plan. To find out more, please visit: <http://atlas.iapb.org>. This infographic is available for free download from <http://tinyurl.com/IAPB-atlas>



Affordable spectacles

VisionSpring is a US-based non-governmental organisation that provides affordable, high-quality, and durable spectacles to organisations and institutions that serve people who live on less than US \$4 per day. They are

seeking partners who would be interested in starting a community eye care outreach programme in their local area, and can also provide affordable spectacles to existing outreach activities. Read more on www.visionspring.org

Courses

MSc Public Health for Eye Care, London School of Hygiene & Tropical Medicine

Fully funded scholarships are available for Commonwealth country nationals. The course aims to provide eye health professionals with the public health knowledge and skills required to reduce blindness and visual disability. For more information visit www.lshtm.ac.uk/study/masters/mscphec.html or email romulo.fabunan@lshtm.ac.uk

Free online courses

ICEH Open Education for eye care programme offers a series of online courses in key topics in public health eye care. All the courses are free to access. Courses: Global Blindness, Eliminating Trachoma, Ophthalmic Epidemiology Basic Principles (1) and Application to Eye Disease (2). More free courses coming! Certification also available. For more information visit <http://iceh.lshtm.ac.uk/oer/>

Subscriptions

Contact Anita Shah
admin@cehjournal.org

Subscribe to our mailing list
web@cehjournal.org or visit
www.cehjournal.org/subscribe

Visit us online

www.cehjournal.org
www.facebook.com/CEHJournal
<https://twitter.com/CEHJournal>

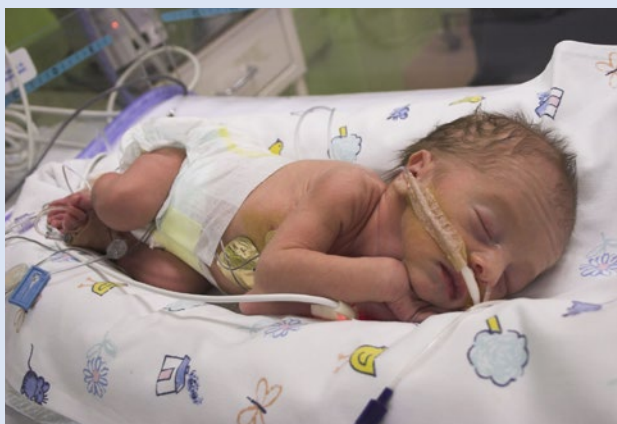Next issue



The next issue of the *Community Eye Health Journal* is our **100th issue** and celebrates the first 30 years of our work.

Key community eye health messages

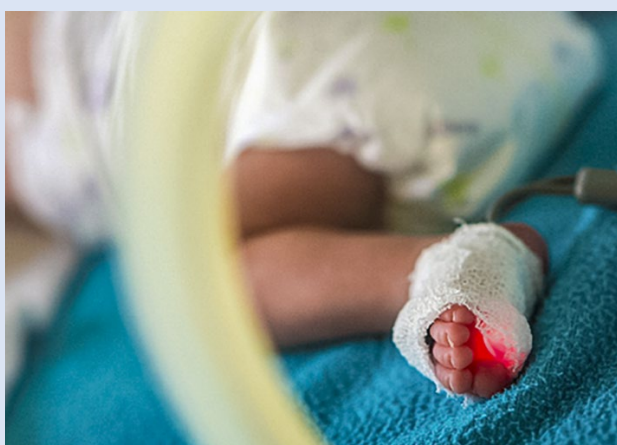Babies born before 36 weeks (preterm) are at risk of retinopathy of prematurity (ROP)



© GERTFRIK/123RF

- The more preterm they are, the greater the risk
- Poor neonatal care increases the risk, even in less premature babies

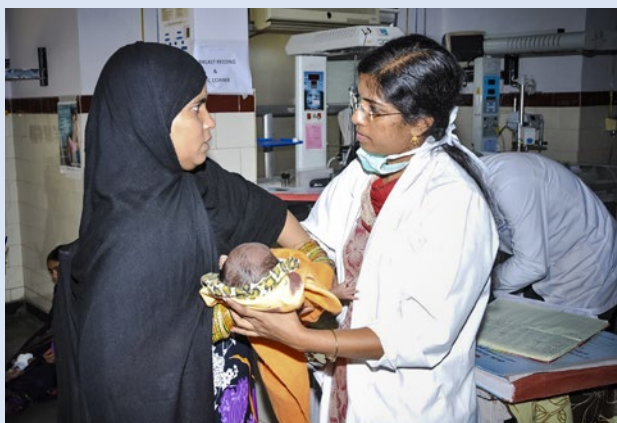It is possible to prevent ROP from causing visual impairment and blindness. This requires:



© NAPOCKASH/SHUTTERSTOCK

- High quality neonatal care. If there is not enough equipment to safely deliver and monitor oxygen, this must be strongly advocated for
- Screening: All babies at risk must be screened before 30 days after birth
- Treatment: Laser treatment should be given urgently, with confluent spots
- Follow-up: All children born preterm are at risk of visual impairment and must be followed up by an ophthalmologist and/or optometrist

Parents are important members of the eye care and neonatal team



PHH

- Involve parents in the day-to-day care of the baby and encourage kangaroo care
- Keep parents informed of the need for screening and the results of screening, and the need for urgent treatment, if required
- Ensure parents understand the need for follow-up visits

Ocular surface disorders



Rohit C Khanna

Director, Gullapalli Pratibha Rao International Centre for Advancement of Rural Eye Care (GPR ICARE), L V Prasad Eye Institute, Hyderabad

The ocular surface comprises the cornea, conjunctiva, eyelids and lacrimal glands and any disorder in these structures can be classified as an ocular surface disorder (OSD). Though the prevalence of OSD is quite high, unfortunately, cases often go undiagnosed or undertreated, due to a lack of understanding of symptoms, and inaccurate evaluation. As people are living longer, these disorders are becoming more prevalent, but awareness about them is quite limited.

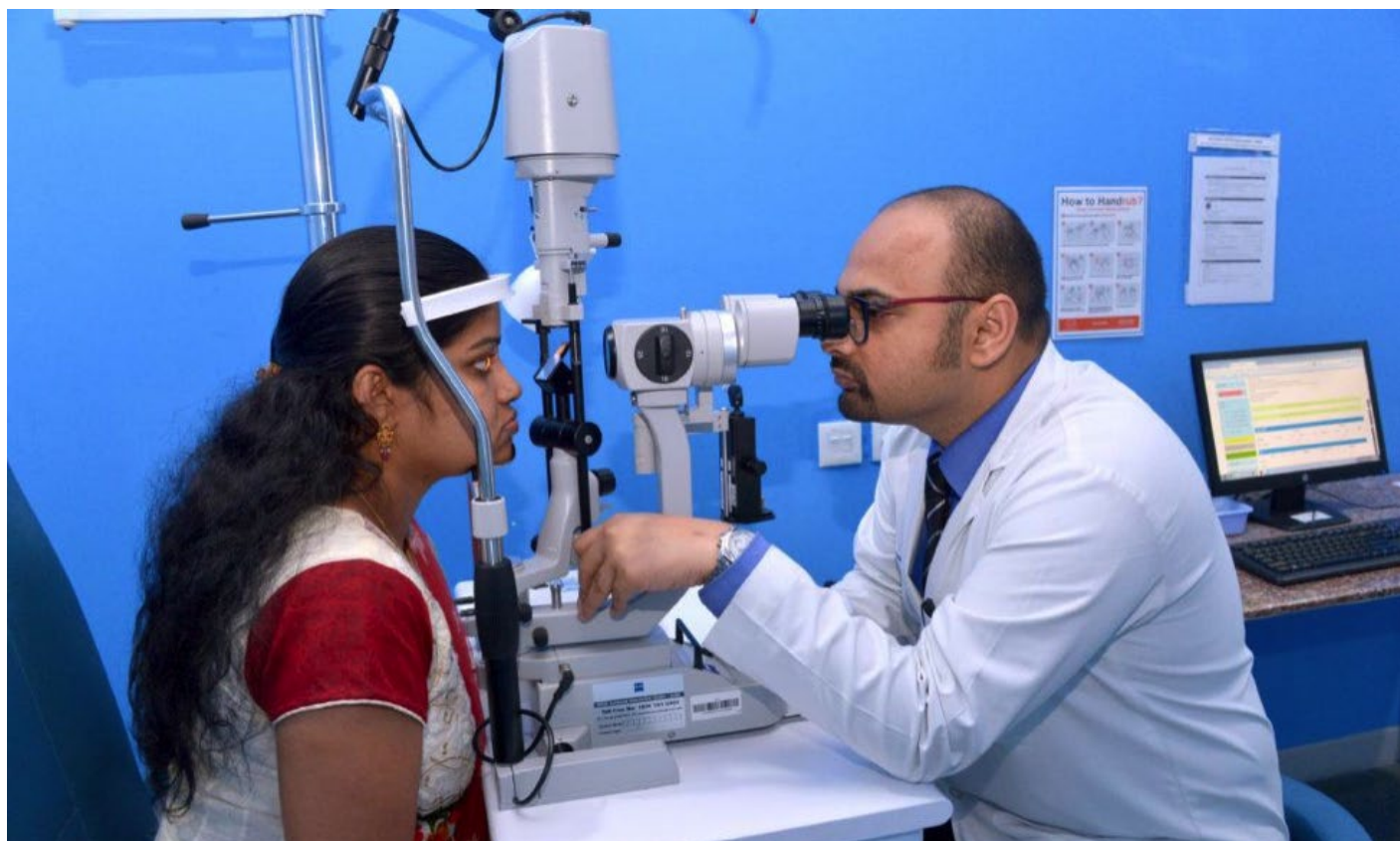OSD includes conditions like Dry Eye Disease (DED), blepharitis and meibomian gland dysfunction (MDG), allergic eye diseases (AED), chemical and thermal burns and so on. Ocular surface diseases can severely affect eyesight and quality of life, and in severe cases, cause blindness. The mode of presentation as well as the severity varies in different populations and this issue will focus on the presentation of OSD in South Asia.

For DED there are no population based studies in South Asia. There are few hospital-based reports published, but the prevalence is quite variable.¹⁻⁴ This is probably due to differences in geographic location as well as lack of standardised questionnaires and objective tests to confirm a diagnosis of dry eye. It's known that increasing age is one of the risk factors for DED; so with an ageing population, we are likely to see more DED in South Asia.

Allergic conjunctivitis (AC) represents a spectrum of disorders comprising seasonal allergic conjunctivitis (SAC), perennial allergic conjunctivitis (PAC), atopic keratoconjunctivitis (AKC), vernal keratoconjunctivitis (VKC) and giant papillary conjunctivitis (GPC). The most common types are SAC and PAC, which are self-limiting conditions and rarely cause significant ocular damage. On the other hand, AKC and VKC are severe

and can affect the cornea and lead to vision loss, either due to the disease itself or due to side effects of corticosteroids, which is one of the mainstays of therapy. Some data on AKC / VKC is available from India, Nepal and Pakistan,⁵⁻⁷ however it is difficult to compare studies as there is no standard validated survey instrument, and so extrapolation of this data to other populations become limited.

For pterygium, a higher prevalence has been reported from countries with increasing geographic latitude and with age.^{8, 9-10} One of the major risk factors identified is ultraviolet light exposure due to outdoor occupations. Other risk factors are male gender and those residing in rural areas.⁸ The mainstay of therapy is surgical excision and different techniques have been described, of which covering bare sclera with conjunctival autograft probably has the lowest rate of recurrence.



A patient is examined for ocular surface disease. INDIA

(C) S.B.N. Charya LVPEI

Continues overleaf ➤

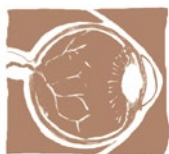Common ocular burns are chemical or thermal, with most chemical burns being due to either acid or alkali. The majority of these chemical burns occur in young males, with lime (*chuna*) being an important cause. Different classification systems are available including Hughes, Roper-Hall, Dua and Holland Mannis classifications. Different modalities of

treatment are available, ranging from first aid as irrigating the eye; medical treatment with topical steroids, antibiotics and cycloplegics and surgical treatment in form of amniotic membrane graft (AMG), limbal stem cell transplantation or simple limbal epithelial cell transplantation (SLET). This issue will provide an overview of different types of OSDs, including dry

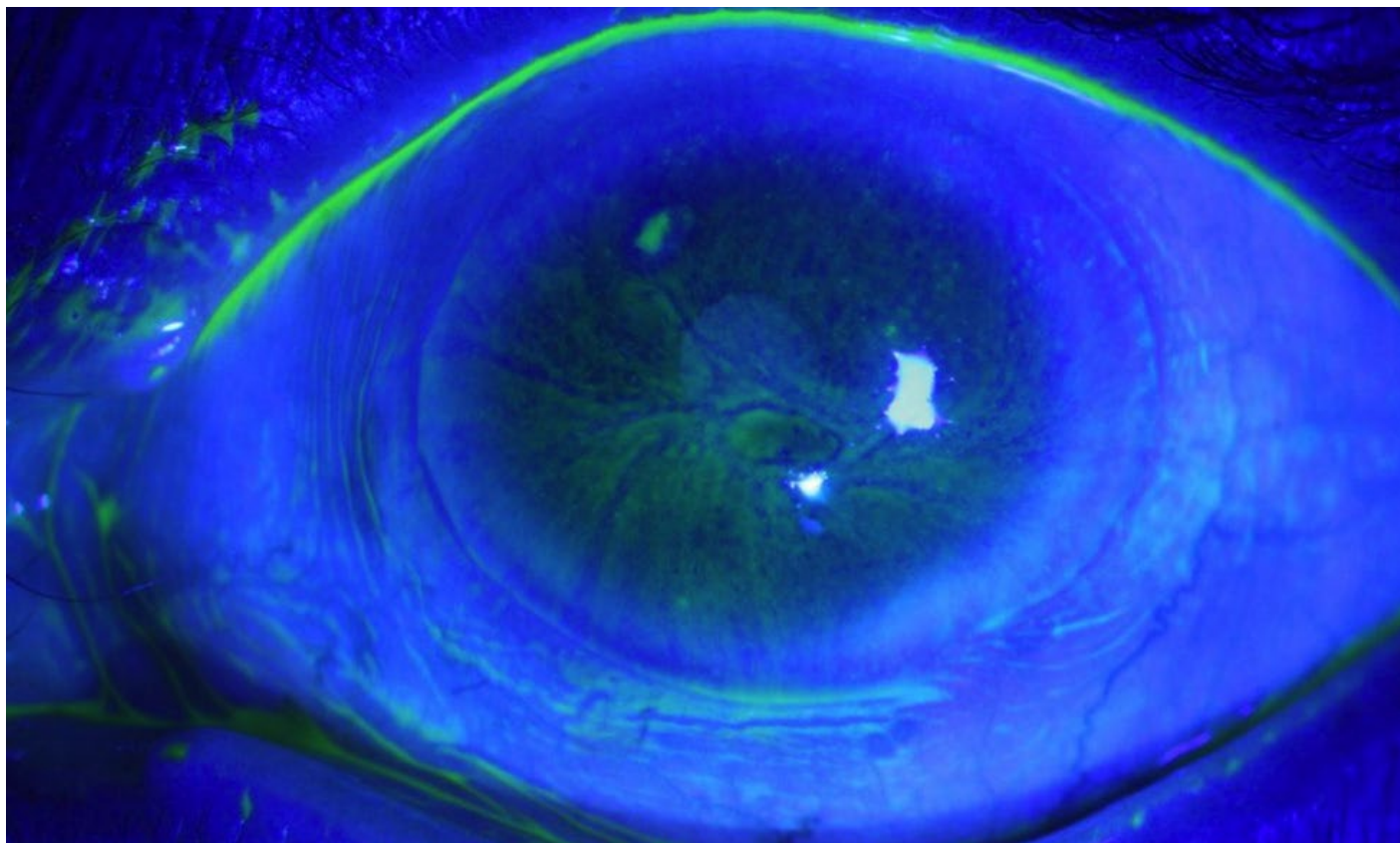
eye, allergic conjunctivitis, pterygium, corneal ulcers and ocular burns in the context of South Asia.

References

- 1 Sahai A, Malik P. Dry eye: prevalence and attributable risk factors in a hospital-based population. *Indian J Ophthalmol*. 2005 Jun;53(2):87-91.
- 2 Gupta N, Prasad I, Jain R, D'Souza P. Estimating the prevalence of dry eye among Indian patients attending a tertiary ophthalmology clinic. *Ann Trop Med Parasitol*. 2010 Apr;104(3):247-55.
- 3 Basak SK, Pal PP, Basak S, Bandyopadhyay A, Choudhury S, Sar S. Prevalence of dry eye diseases in hospital-based population in West Bengal, Eastern India. *J Indian Med Assoc*. 2012 Nov;110(11):789-94.
- 4 Gupta N, Prasad I, Himashree G, D'Souza P. Prevalence of dry eye at high altitude: a case controlled comparative study. *High Alt Med Biol*. 2008 Winter;9(4):327-34.
- 5 Pokharel N, Shah DN, Choudhary M. Vernal keratoconjunctivitis: modes of presentation in Nepalese population. *Kathmandu University medical journal*. 2007;5(4):526-30.
- 6 So RA, Mufti A. Vernal Keratoconjunctivitis in Kashmir: A temperate zone. *International ophthalmology*. 2016. Dec;36(6):875-879.
- 7 Saboo US, Jain M, Reddy JC, Sangwan VS. Demographic and clinical profile of vernal keratoconjunctivitis at a tertiary eye care center in India. *Indian journal of ophthalmology*. 2013;61(9):486-9.
- 8 Liu L, Wu J, Geng J, Yuan Z, Huang D. Geographical prevalence and risk factors for pterygium: a systematic review and meta-analysis. *BMJ Open*. 2013 Nov 19;3(11):e003787.
- 9 Zhao L, You QS, Xu L, Ma K, Wang YX, Yang H, Jonas JB. 10-year incidence and associations of pterygium in adult Chinese: the Beijing Eye Study. *Invest Ophthalmol Vis Sci*. 2013 Feb 27;54(2):1509-14.
- 10 Nemesure B, Wu SY, Hennis A, Leske MC; Barbados Eye Studies Group.. Nine-year incidence and risk factors for pterygium in the Barbados eye studies. *Ophthalmology*. 2008 Dec;115(12):2153-8.



Prevention, diagnosis & management of dry eye in South Asia



(c) L V Prasad Eye Institute

Figure 1. Fluorescein staining of cornea as seen with cobalt blue filter



Varsha M Rathi

Faculty, Tej Kohli Cornea Institute, Gullapalli Pratibha Rao International Center for Advancement of Rural Eye Care, L V Prasad Eye Institute (LVPEI), Hyderabad, India



Virender S Sangwan

Faculty, Tej Kohli Cornea Institute, Kallam Anji Reddy Campus, L V Prasad Eye Institute (LVPEI), Hyderabad, India.

Introduction

Dry eye is a condition that affects the tear film and affects the ocular surface that includes the conjunctiva and cornea.¹ Dry eye, being a chronic disease, results in health related quality of life issues and economic problems due to loss of productive working days and the cost of medical treatment. Untreated dry eye may result in corneal surface ulceration and opacification leading to corneal blindness.

Definition of dry eye

In 2007, the International Dry Eye Workshop (DEWS) report defined

dry eye as a multifactorial inflammatory disease of the tears and ocular surface, resulting in discomfort and visual disturbance, unstable tear film and ocular surface damage.¹

Classification and etiology

The dry eye condition is classified as evaporative dry eye and aqueous tear deficient dry eye.^{2,3} Aqueous deficient dry eye is further subdivided as Sjogren syndrome dry eye and non-Sjogren dry eye.

Sjogren's syndrome is a chronic inflammatory connective tissue disorder more common in females, who may be around 40 years of age. These patients may have dry eye and dry mouth. Primary Sjogren's syndrome is without systemic disease; Secondary Sjogren's is with systemic disease.

Non-Sjogren's dry eye is seen in patients having Graft versus Host disease, trachoma, conjunctival cicatrizing disorders and use of drugs such as antihistamines, decongestants, antipsychotic drugs, antidepressants and antihypertensives. Evaporative dry eye is most commonly caused by

meibomian gland disease.

Epidemiology

Dry eye is more common in elderly females.⁴ Predisposing factors include collagen vascular disease, diabetes, allergy, antihistamines, pterygium and climate.^{4,5}

Diagnosis of dry eye

History taking, clinical examination followed by investigations are done to diagnose dry eye.

Symptoms

Patients with dry eye have a long history of symptoms such as of irritation and sandy or gritty sensation in the eyes. The symptoms may be mild to severe, and infrequent to long standing. The patients may have worsening of symptoms on prolonged visual work, intolerance to low humidity, feeling of dry eye and irritation. Dry eye is usually symptomatic although Sullivan et al have shown that 40% of patients having dry eye were asymptomatic and sometimes the symptoms may not correlate with the signs.⁶

Continues overleaf ➤

There are various questionnaires such as Ocular Surface Disease Index (OSDI) and McMonnies questionnaire to identify, diagnose and manage dry eyes.^{7,8}

Clinical examination

Observation of the lids, conjunctiva and cornea should be done first before performing any test. The following is the sequence of examining a patient of dry eye.

1. Initial examination of lids and the ocular surface
2. TBUT – Tear film break up time after instillation of fluorescein dye
3. Corneal staining with fluorescein or lissamine green (between 1-4 minutes of lissamine green instillation)
4. The Schirmer 1 test (or phenol red thread test Schirmer test with anaesthesia) can be performed to determine the basal tear production. Tear osmolality should be measured after examination, if available.

Diagnostic tests

Schirmer test – The test is performed by putting a filter paper strip in the middle of lower fornix.⁹ After five minutes, the wetting of the filter strip is assessed. A wetting of 10mm or more is considered normal. Before applying a filter strip, excess tears should be wiped out otherwise the results may be showing a false high. Repeatability of this test and correlation with patient symptoms is poor.

Phenol red thread test – This test measures the tear volume. Phenol red, being pH sensitive, changes from red to yellow when exposed to tears.¹⁰ A 70mm thread is placed in lower fornix and wetting is measured after 15 seconds. The normal values range between 9mm-20mm and less than 9 mm is considered dry eye. Patel et al have shown that a value of 15 mm of wetting correlated with aqueous deficient and 22 mm with non-aqueous deficient dry eye.¹¹

Tear osmolality – This increases in patients with dry eye disease.

Tear film breakup time (TBUT) – A fluorescein strip is applied in the lower fornix and removed. The patient is asked to blink normally and then to stop blinking. The time taken from stopping blinking to the appearance of the first dark spot in the tear film indicates TBUT. A TBUT of <10 seconds is abnormal.

Videokeratography and keratometry – This can also be used to assess the TBUT. Normal values for break-

ing of mires during keratometry are more than 15 seconds.

Meibography – Technological advances in the field of digital imaging have helped in assessing the meibomian glands, which if dysfunctional can result in evaporative dry eye. Various methods are available to do so including auto-refractometer.

Corneal staining – Fluorescein staining of cornea appears greenish and is viewed using cobalt blue filter (Figure 1). The pattern of staining gives a clue to the etiology of dry eyes e.g. inferior corneal staining in patients having lagophthalmos or inability to close the eye lids; interpalpebral staining in evaporative dry eyes.

Rose Bengal stain – It stains dead and devitalised cells of cornea and conjunctiva. The patients have severe stinging when Rose Bengal stain is used. One can also use lissamine green stain. Diagnosis is based on a combination of history, clinical examination and the investigations.

Management

Management depends on the severity of dry eye and response to the treatment.

Artificial tears and lubricating eye drops – This should be given to dry eye which is aqueous deficient. Artificial tears that merely increase tear volume may worsen symptoms in patients with a lipid deficiency.

Tear retention with punctal occlusion – This may be indicated in patients who have symptomatic dry eyes, when Schirmer's test is <5 mm and there is ocular surface staining. These can be done either with cautery or with punctal plugs (absorbable and non-absorbable).

Management of lids – Treat inflammation of the meibomian glands with hot bathing over closed eyelids followed by expression of the meibomian secretions. Use of lubricating eye drops, oral doxycycline and tetracycline may be helpful.

Key message

Dry eye is a multifactorial disease. It is important to determine whether it is aqueous deficient or evaporative dry eye or a combined one. Success of the treatment is dependent on proper understanding of the cause of dry eye and approach to the management.

Determination of tear meniscus height is important. Schirmer's test will help differentiate aqueous

deficient from evaporative dry eye. This should be done in all patients. Corneal staining with fluorescein, Rose Bengal and Lissamine green dyes will help assess damage to the ocular surface. Based on the level of damage, Schirmer's test values and TBUT values, management can either be with lubricating eye drops, anti inflammatory agents, environmental modifications, or treatment of inflammation of the meibomian glands. The treating physicians should modify treatment based on patients' symptoms.

References

- 1 The definition and classification of dry eye disease: report of the Definition and Classification Subcommittee of the International Dry Eye WorkShop (2007). *Ocul Surf*.2007 Apr;5(2):75-92.
- 2 Methodologies to diagnose and monitor dry eye disease: report of the Diagnostic Methodology Subcommittee of the International Dry Eye WorkShop (2007). *Ocul Surf*.2007 Apr;5(2):108-52.
- 3 Lemp MA. Report of the National Eye Institute/ Industry workshop on Clinical Trials in Dry Eyes. *CLAO J*.1995 Oct;21(4):221-32.
- 4 Gayton JL. Etiology, prevalence, and treatment of dry eye disease. *Clin Ophthalmol*.2009;3:405-12.
- 5 Kaiserman I, Kaiserman N, Nakar S, Vinker S. Dry eye in diabetic patients. *Am J Ophthalmol*.2005 Mar;139(3):498-503.
- 6 Sullivan BD, Crews LA, Messmer EM, et al. Correlations between commonly used objective signs and symptoms for the diagnosis of dry eye disease: clinical implications. *Acta Ophthalmol*.2014 Mar;92(2):161-6.
- 7 Schiffman RM, Christianson MD, Jacobsen G, Hirsch JD, Reis BL. Reliability and validity of the Ocular Surface Disease Index. *Arch Ophthalmol*.2000 May;118(5):615-21.
- 8 McMonnies CW, Ho A. Patient history in screening for dry eye conditions. *J Am Optom Assoc*.1987 Apr;58(4):296-301.
- 9 Sue Stevens. Schirmer's test. *Community Eye Health Journal* published online 01 December 2011. <https://www.cehjournal.org/article/schirmers-test/> (accessed 12 September, 2016)
- 10 McGinnigle S, Naroo SA, Eperjesi F. Evaluation of dry eye. *Surv Ophthalmol*.2012 Jul-Aug;57(4):293-316.
- 11 Patel S, Farrell J, Blades KJ, Grierson DJ. The value of a phenol red impregnated thread for differentiating between the aqueous and non-aqueous deficient dry eye. *Ophthalmic Physiol Opt*.1998 Nov;18(6):471-6.



Pterygium: epidemiology prevention and treatment



Prof Dr Sanjay Kumar Singh

Director, Eastern Regional Eye Care Programme, Biratnagar, Nepal.

Epidemiology

Pterygium is a degenerative disorder of the conjunctiva. It is usually seen as a triangular fleshy fibrovascular proliferation from the bulbar conjunctiva onto the cornea, located mostly on the nasal side. Though it occurs worldwide, its prevalence is high in the "pterygium belt" between 30 degrees north and 30 degrees south of the equator.¹ The prevalence of pterygium is reported to be 3% in Australians, 23% in blacks in United States, 15% in Tibetans in China, 18% in Mongolians in China, 30% in Japanese and 7% in Singaporean Chinese and Indians.²⁻⁷

In a population-based study from rural central India, prevalence of pterygium increased from 6.7±0.8% in the age group from 30-39 years to 25.3±2.1% in the age group of 70-79 years. Three population based studies have described the incidence of pterygium. Barbados eye study has described the nine year incidence of pterygium to be 11.6% (95% CI, 10.1-13.1), the Beijing Eye Study described the 10 year incidence of pterygium in the adult Chinese population to be 4.9%, and the five year cumulative incidence in Bai Chinese population in a rural community was 6.8% (95% CI, 5.2-8.4).⁸⁻¹⁰

Risk factors and pathogenesis

These population-based studies suggest that cumulative ultraviolet light exposure due to outdoor occupation is a major risk factor for the development of pterygium. Other factors associated with pterygium development are age, being male and having dry eyes.¹¹⁻¹³ Genetic factors, tumor suppressor gene p53 and other genes may be involved in the pathogenesis of pterygium.¹⁴

A study indicated a two-stage hypothesis for pterygium pathogenesis: initial disruption of the limbal barrier and progressive active "conjunctivalisation" of the cornea.¹⁵ Identifi-

cation of Fuchs Flecks at the head of pinguecula, primary pterygium, recurrent pterygium, and macroscopically normal nasal and temporal limbus may represent precursor lesions to UV associated ocular surface pathology.¹⁶

Prevention

Avoidance of environmental risk factors like sunlight, wind and dust by wearing UV rays protecting sunglasses and hat may prevent development of pterygium. These protective measures may help to prevent recurrence of pterygium after surgery. Similarly, wearing of eye safety equipment is recommended in environment exposed to chemical pollutants as a preventive measure for pterygium.

Indication for surgery

The main indication for pterygium surgery is visual disturbance secondary to encroachment over the pupillary area or induced astigmatism. Other indications which can be considered are, restriction in eye movements, chronic redness and foreign body sensation, and cosmetic concerns.¹⁷

Management

Surgery is the mainstay of treatment for pterygium causing visual disturbances. The primary complication of pterygium surgery is recurrence defined by regrowth of fibrovascular tissue across the limbus and onto the cornea. No uniformity of opinion exists regarding the ideal pterygium excision procedure associated with lowest recurrence rate. Bare sclera technique, which is widely used in the developing world for the ease and speed of surgery, is associated with high recurrence rates.¹⁸ Other adjunctive therapies combined with bare sclera technique have significantly reduced the recurrence rate (2% to 15%).¹⁹ Application of different agents like Strontium 90, Beta irradiation and cytotoxic drugs like Mitomycin-C and 5-Fluorouracil to the scleral bed have been tried but sight threatening complications like inflammatory scleritis, scleromalacia and loss of the eye have been occasionally reported.²⁰ Amniotic membrane transplan-

tation has been used after bare sclera technique with a reported recurrence rate of 4% to more than 60%.^{21,22}

Currently, the most widely used procedure is pterygium excision with conjunctival autograft.²³ Superior bulbar conjunctiva has been used widely since the early 1980s and is associated with recurrence rate of approximately 2% to 12% along with few complications.²⁴⁻²⁶ In the 1980s, Barraquer introduced the concept that removal of Tenon's layer may be important in reducing recurrence rate after pterygium removal as the tenon is the main source of fibroblasts.²⁷ This was also emphasised by Solomon et al who combined this technique with Mitomycin-C application and amniotic membrane transplantation to achieve a low recurrence rate.²⁸ A near zero recurrence rate with a good aesthetic result can be achieved by using Pterygium Extended Removal Followed by Extended Conjunctival Transplantation (P.E.R.F.E.C.T.).²⁹⁻³¹ There is no ideal technique for conjunctival autografting which is safe, fast, easy and inexpensive. Various methods such as sutures, fibrin glue, autologous serum and electrocautery have been used for conjunctival autografting.^{32,33} Surgical steps for pterygium excision with conjunctival autograft that we have adopted at our hospitals under Eastern Regional Eye Care Programme in the eastern part of Nepal are as follows:

Anaesthesia: Peribulbar anaesthesia is preferable over the topical or subconjunctival to avoid pain during operation and to have smooth surgical procedure.

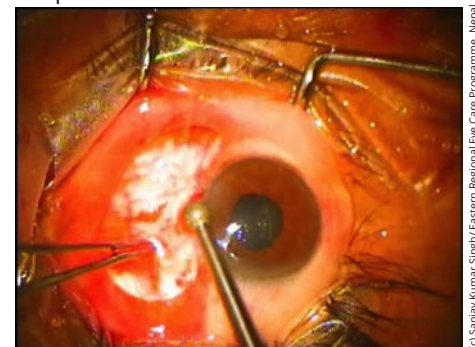


Figure 1. A diamond burr is used for smoothing of corneal surface

(c) Sanjay Kumar Singh/ Eastern Regional Eye Care Programme, Nepal

Continues overleaf ➤

Pterygium excision: Pterygium body is excised carefully with conjunctival scissors and the head of pterygium can be removed from cornea by using a 15 degree Bard Parker blade. Tenons and subtenon tissue must be removed carefully as much as possible. Remaining pterygium tissues from over the corneal surface can be removed with a diamond burr.

Conjunctival autograft preparation: The conjunctival defect created by pterygium excision should be measured with a caliper and the superior bulbar conjunctiva should be marked by a marker. It is always preferable to use the marker to create exactly the same size of the graft. After marking, a subconjunctival injection of normal saline, around 2 ml, is injected on the superior bulbar conjunctiva to create the conjunctival balloon. A thin layer of conjunctival graft, devoid of tenons and subtenon tissue is prepared.

Conjunctival grafting: The thin conjunctival graft is placed with correct orientation on the area of the conjunctival defect created by pterygium excision. The marker helps to identify the correct orientation of the graft. The conjunctival graft can be sutured with the 8/0 Vicryl or 10/0 Nylon sutures or can be glued with fibrin glue.

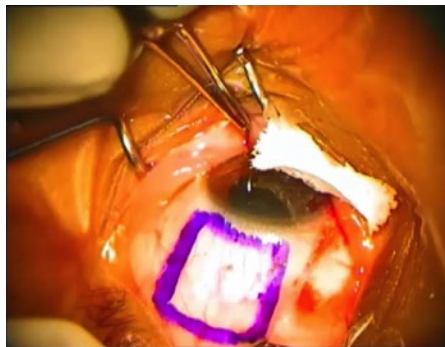


Figure 2. A conjunctival autograft marking

Conjunctival grafting with fibrin glue is a faster procedure and patients complain of less pain in the post-operative period.

Post-operative management:

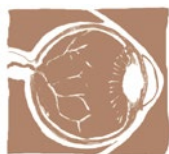Antibiotic and steroid eye drops are given in tapering doses for one month.

Conclusion

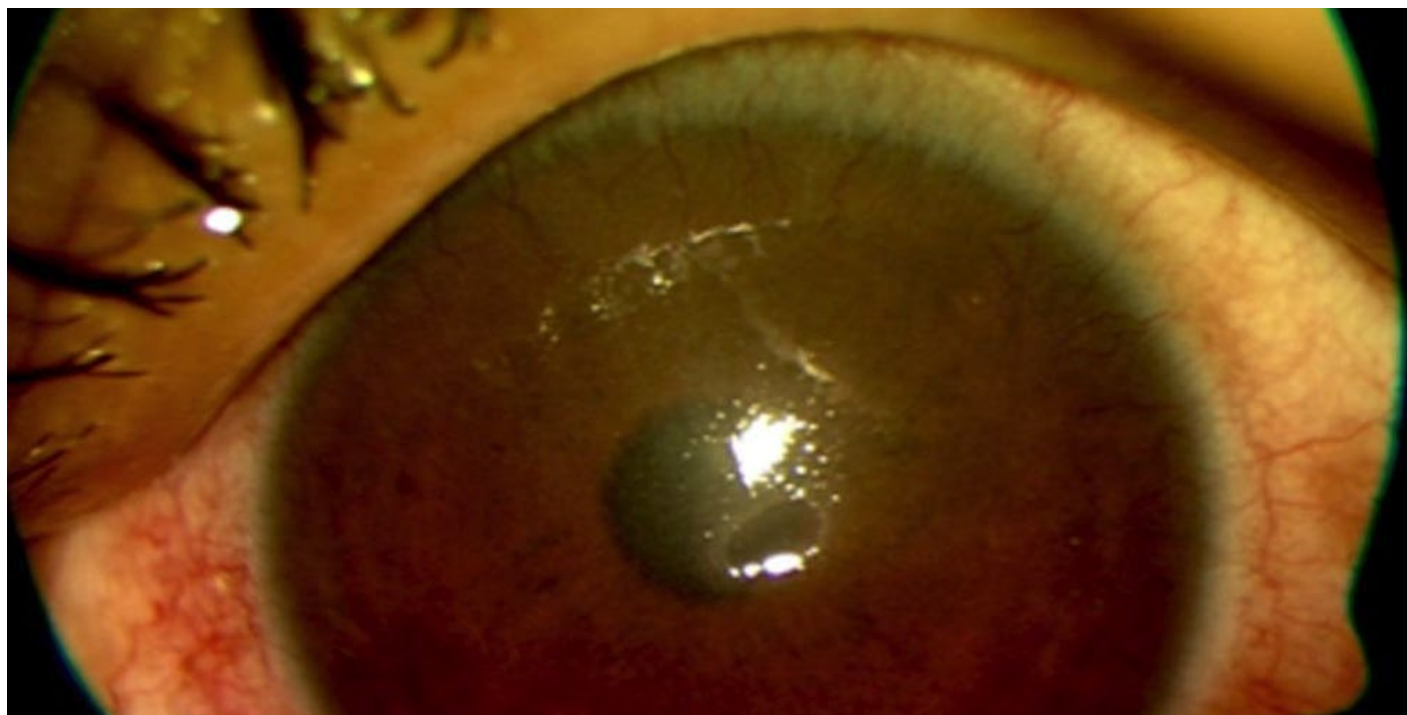
Many ophthalmologists think that pterygium is a trivial condition for which not much time should be expended in surgery and for which the financial remuneration is low.³⁴ But the patients want a cure, free of recurrence with good cosmesis after surgery. Pterygium excision with conjunctival autograft with fibrin glue offers a low recurrence rate, good cosmetic outcome with a reasonable speed of the pterygium surgery.

References

- Detels R, Dhir SP. Pterygium: a geographical study. *Arch Ophthalmol*. 1967;78: 485-491.
- McCarty CA, Fu CL, Taylor HR. Epidemiology of Pterygium in Victoria, Australia. *Br J Ophthalmology*. 2000;84:289-292.
- Luthra R, Nemesure BB, Wu SY, et al. Frequency and Risk Factors for Pterygium in the Barbados Eye Study. *Arch Ophthalmology*. 2001;119:1827- 1832.
- Lu P, Chen X, Kang Y, et al. Pterygium in Tibetans: a population-based study in China. *Clin Experiment Ophthalmol*. 2007;35:828-833.
- Lu J, Wang Z, Lu P, et al. Pterygium in an aged Mangolian Population: a population based study in China. *Eye (Lond)* 2009;23:421-427.
- Shirma H, Higa A, Sawaguchi S, et al. Prevalence and risk factors of Pterygium in southwestern island of Japan: the Kumejima Study. *Am J Ophthalmol*. 2009;148:766-771.e761.
- Ang M, Li X, Wong W, et al. Prevalence of and racial differences in pterygium a multiethnic population study in Asians. *Ophthalmology*. 2012;119:1509-1515.
- Nemesure B, Wu SY, Hennis A et al. Nine-year incidence and risk factors for pterygium in the Barbados eye studies. *Ophthalmology*. 2008;115:2153-2158.
- Zhao L, You QS, Xu L, et al. 10 year incidence and association of Pterygium in adult Chinese: the Beijing Eye Study. *Invest Ophthalmol Vis Science*. 2013; 54:1509-1514.
- Lan Li, Hua Zhong, Ermio Tian et al. Five-Year Incidence and Predictors for Pterygium in a Rural Community in China: The Unnan Minority Eye Study. *Cornea*. 2015;34:1564-1568.
- Wong TY, Foster PJ, Johnson GJ, et al. The Prevalence and risk factors for pterygium in an adult Chinese population in Singapore: the Tanjong Pagar survey. *Am J Ophthalmol*. 2001;131:176-183.
- Saw SM, Banerjee K, Tan D. Risk factors for the development of pterygium in Singapore: a hospitalbased case control study. *Acta Ophthalmol Scand*. 2000;78:216-220.
- Ishioka M, Shimmura S, Yagi Y et al. Pterygium and dry eye. *Ophthalmologica*. 2001;215:209- 211.
- Liu T, Liu Y, Xie L, et al. Progress in the pathogenesis of pterygium. *Current Eye Res*. 2013;38:1191-1197.
- M.T. Coroneo, N. Di Girolamo and D. Wakeeld. The pathogenesis of pterygia. *Current Opinion in Ophthalmology*. 1999;10:282-288.
- Matthew H. Ip, Jeanie J Chui, Lien Tat and Minas T. Coroneo. Significance of Fuchs Flecks in Patients With Pterygium/Pinguecula: Earliest Indicator of Ultraviolet Light Damage. *Cornea*. 2015;34:1560- 1563.
- Lawrence W. Hirst. The Treatment of Pterygium. *Survey of Ophthalmology*. 2003;48:2: 145-179.
- Lawrence W. Hirst. Prospective Study of Primary Pterygium surgery using Pterygium Extended Removal Followed by Extended Conjunctival Transplantation. *Ophthalmology*. 2008;115:1663- 1672.
- Simsek T, Gunlap I, Atilla H. Comparative efficacy of beta irradiation and mitomycin-C in primary and recurrent pterygium. *Eur J Ophthalmol*. 2001;11:126-132.
- Dougherty PJ, Harden DR, Lindstrom RL. Corneoscleral melt after pterygium surgery using a single intraoperative application of mitomycin-C. *Cornea*. 1996;15:537-540.
- Ma DH, See LC, Liao SB, Tsai RJ. Amniotic Membrane graft for primary pterygium: comparison with conjunctival autograft and topical mitomycin C treatment. *Br J Ophthalmol*. 2000;84:973-978.
- Essex RW, Snibson GR, Daniell M, Tole DM. Amniotic membrane grafting in the surgical management of primary pterygium. *Clin. Experiment Ophthalmol*. 2004;32:501-504.
- Kenyon KR, Wagoner MD, Hettinger ME. Conjunctival autograft transplantation for advanced and recurrent pterygium. *Ophthalmology*. 1985;92:1461-1470.
- Young AL, Leung GY, Wong AK et al. A randomized trial comparing 0.02% mitomycin-C and limbal conjunctival autograft after excision of primary pterygium. *Br J Ophthalmol*. 2004;88:995-997.
- Mejia LF, Sanchez JG, Escobar H. Management of primary pterygia using free conjunctival and limbal conjunctival autografts without antimetabolites. *Cornea*. 2005;24:972-975.
- Fernandes M, Sangwan VS, Bansal AK et al. Outcome of pterygium surgery: analysis over 14 years. *Eye*. 2005;19:1182-1190.
- Barraquer JL. Etiology, pathogenesis and treatment of the pterygium. *Trans New Orleans Acad Ophthalmol*. 1980;167-178.
- Solomon A, Pires RT, Tseng SC. Amniotic membrane transplantation after extensive removal of primary and recurrent pterygia. *Ophthalmology*. 2001;108:449-460.
- Hirst LW. Prospective study of Primary Pterygium Surgery using Pterygium Extended Removal Followed by Extended Conjunctival Transplantation. *Ophthalmology*. 2008;115:1663-1672.
- Hirst LW. Cosmesis after Pterygium extended removal followed by extended conjunctival transplantation as assessed by a new, web-based grading system. *Ophthalmology*. 2011;118:1739- 1746.
- Hirst LW. Pterygium Extended Removal Followed by Extended Conjunctival Transplantation: But on which eye? *Cornea*. 2013;32:799-802.
- Vanitha Ratnalingam, Andrew Lim Keat Eu, Gem Leong et al. Fibrin Adhesive is Better Than Sutures in Pterygium Surgery. *Cornea*. 2010;29:485-489.
- Fan Xu, Min Li, Yumei Yan et al. A Novel Technique of Sutureless and Glueless Conjunctival Autografting in Pterygium Surgery by Electrocautery Pen. *Cornea*. 2013;32:290-295.
- Essex RW, Snibson GR, Daniell M et al. Amniotic Membrane grafting in the surgical management of primary pterygium. *Clin Experiment Ophthalmol*. 2004;32:501-504.



Allergic conjunctivitis



(c) V Rathi/LVPEI

Roughness of epithelium as seen in shield ulcer



Varsha M Rathi

Faculty, Tej Kohli Cornea Institute, Gullapalli Pratibha Rao International Center for Advancement of Rural Eye Care, L V Prasad Eye Institute, Hyderabad, India



Somasheila I Murthy

Faculty, Tej Kohli Cornea Institute, L.V. Prasad Eye Institute, Kallam Anji Reddy Campus, Hyderabad, India

The diagnosis of allergic diseases has increased in the last few decades and allergic conjunctivitis has emerged as a significant problem, which can cause severe ocular surface disease. Patients complain of itching, watering and redness. It can result in decreased quality of life, as patients with severe symptoms, if left untreated or treated poorly, may become

school dropouts, unable to work outdoors and sometimes fail to sleep. The symptoms are aggravated by exposure to dry and windy climates.^{1,2} This article aims to provide a brief overview of the management of allergic conjunctivitis. The most important symptom of allergic conjunctivitis is itching. Table 1 lists spectrum of disorders of allergic conjunctivitis.³

Epidemiology

The diagnosis of allergic conjunctivitis is on the increase. SAC and PAC accounts for 15-20% of cases of allergic conjunctivitis.⁴ The disease is more common in hot, humid tropical climates.⁵ VKC has been reported from many Asian countries e.g. Nepal, Pakistan and India.^{2,6,7} VKC and AKC may cause corneal and ocular surface involvement leading to severe

visual loss. Numerous factors such as changing climates, increasing pollution, genetics, cigarette pollutants and occurrence of allergy in early childhood have been proposed as causative agents or risk factors. Significant correlations have been observed with mixed pollen, threshold dust and raw cotton with allergic rhinitis and allergic conjunctivitis.⁸ Seasonal peak is seen during April to August in patients having VKC.⁹

Classification

Seasonal allergic conjunctivitis

This condition is common, is seen among all ages and occurs seasonally when pollen is released in May and June. Itching followed by watering and a burning sensation is seen in these patients. Sometimes, it may be associated with a running nose

Table 1. Disorders of allergic conjunctivitis

Mild allergic conjunctivitis	Severe allergic conjunctivitis	Chronic microtrauma related disorders
Seasonal conjunctivitis (SAC)	Vernal keratoconjunctivitis (VKC)	Contact lens induced papillaryconjunctivitis (CLPC)
Perennial conjunctivitis (PAC)	Atopic keratoconjunctivitis (AKC)	Giant papillary conjunctivitis (GPC)

Continues overleaf ➤

(allergic rhinitis or rhinoconjunctivitis). Patients may complain of sinus pressure behind the eye.

Perennial allergic conjunctivitis

PAC has similar signs and symptoms to SAC and as the name suggests it occurs throughout the year. PAC is due to allergy to animal dander, mites and feathers. The frequency of occurrence increases as the age increases.¹⁰ The patients have itching, redness and swelling of conjunctiva. Corneal involvement in SAC and PAC is rare.⁴

Vernal keratoconjunctivitis

VKC is a disease of warm climates and occurs predominantly in young males (8-12 years of age).^{2,11} Although VKC is more common in children, adults may also have VKC.^{12,13} It is a bilateral disease and may worsen with exposure to wind, dust and sunlight. These patients may have positive history of asthma or eczema. Patients present with severe itching (rubbing of eyes usually with a knuckle), redness, discharge, and photophobia. The mucus discharge

is thread-like. School-going children may drop out from going to school because of severe itching and photophobia.

Three clinical forms of VKC are described: limbal or bulbar, palpebral and mixed (Figure 1). Limbal form is more common in dark skinned individuals. In Asia, the mixed form is more common compared to the limbal form, which is seen in Africans.⁷ However, studies from India and Nepal have reported that the bulbar form of the disease is common in some areas.^{2,9}

Limbal or bulbar form may present as gelatinous thickening of the limbus, presence of papillae at the limbus and yellow Horner-Tranta's dots (Figure 1) usually at the superior limbus. These dots are seen when the disease is active and indicate severity of the disease.

The hallmark of the palpebral VKC is presence of giant papillae, which are seen on everting the upper lid – the giant papillae have a cobble stone appearance (Figure 1). This thickening of the upper lid may be associated with drooping of the lid (ptosis). Con-

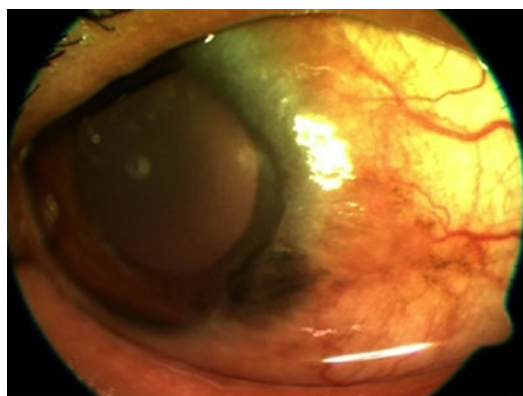
junctival pigmentation is common in patients having VKC.¹⁴

The mixed form of VKC has features of both palpebral and limbal VKC. Corneal involvement in VKC may occur as corneal epithelial punctate keratitis, and where the epithelial erosions may coalesce and form a vernal or a shield ulcer. Presence of shield ulcer will worsen patients' symptoms and affect vision. These ulcers are oval and are usually present in the upper part of the cornea. The shield ulcers are classified based on the presence of white material at the base of the ulcer. Based on the grades of shield ulcer, the treatment options differ.¹⁵

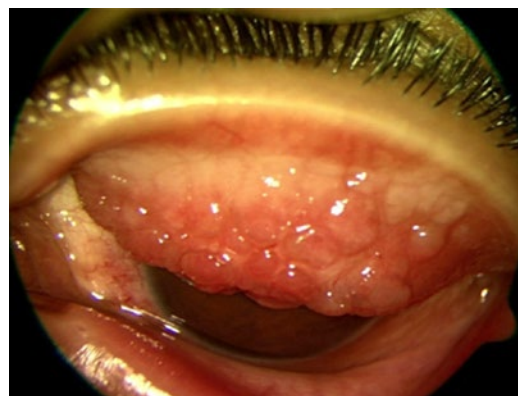
Atopic keratoconjunctivitis:

AKC is a bilateral disease of ocular surface and lids, which occurs throughout life. The patients will have eczematous skin lesions of the body. The conjunctiva may have papillae or Trantas dots. Cataract formation can occur in these patients. Table 2 shows the differentiating features of VKC and AKC.

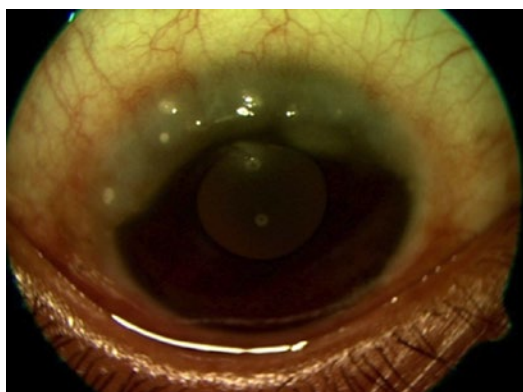
Figure 1. Clinical forms of VKC: Limbal or bulbar, palpebral and mixed



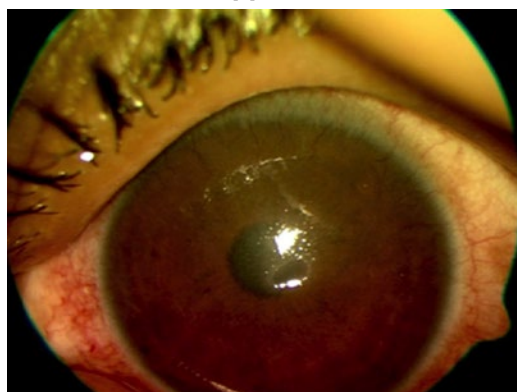
Limbal form of VKC: Gelatinous translucent appearance



Palpebral form of VKC: Cobble stone papillae seen after flipping of upper lid



Yellow Horner Trantas dots: more the dots, severe is the disease



Roughness of epithelium as seen in shield ulcer

Continues overleaf ►

Table 2. Differentiating features of vernal and atopic keratoconjunctivitis

	VKC	AKC
Age	Young	Old
Sex	Males > Females	Equal ratio
Season	Spring	Perennial
Duration	Limited	Chronic
Skin involvement	No	Yes, extra lid fold, maceration of canthi
Punctal stenosis	No	Yes
Conjunctiva	Upper tarsal conjunctiva	Lower tarsal conjunctiva
Conjunctival scarring	Rare	Common
Cornea	Shield ulcer	Epithelial defects
Scarring	Peripheral	Central
Vascularisation	Rare	Common

VKC: vernal keratoconjunctivitis AKC: Allergic keratoconjunctivitis

Giant papillary conjunctivitis:

The presence of a contact lens, ocular prosthesis or sutures may sensitise and cause trauma to the upper tarsal conjunctiva with the formation of giant papillae. Removal of these external agents will reduce the papillae. Toxic allergic reactions may also be due to drugs such as neomycin, atropine, epinephrine or preservatives in medicines such as thiomer-sol.¹⁶

Contact hypersensitivity reactions:

The pattern of involvement depends upon severity of the reaction and the site of contacts. Patients may have lid swelling, redness, chemosis, follicular reaction and later sometimes cicatrisation. The corneal involvement may be in the form of superficial punctate keratitis, pseudodendrites or grayish stromal infiltrates.¹⁷

Complications

Most often, the complications are because of poor compliance to treatment on the part of patient, or inadequate control of the disease when it presents in its severe form. Common complications include dry eye, infection and corneal scar. Chronicity of the untreated disease may lead to vision threatening problems like limbal stem cell deficiency (LSCD) and secondary keratoconus due to rubbing of the eyes.

As the treatment involves use of corticosteroids, steroid-induced raised in-

traocular pressure and cataract have been reported in these patients.⁷ Complications may lead to irreversible visual loss in some patients.⁷ Both the complications, keratoconus and LSCD need timely surgical treatment to prevent visual malfunction.

Diagnosis

Appropriate management of allergic conjunctivitis needs a correct diagnosis. Figure 2 gives a guide for such diagnosis and ways to differentiate from other causes of red eyes. Presence of itching is a hallmark of ocular allergy.

Management

Though some authors have described management protocols, there are no universally accepted protocols of management for allergic eye diseases.^{11,12} Various drugs are available and the treatment options vary based on the severity of the disease. It is important to avoid any known allergen or reduce exposure to it by using wrap around glasses, by changing the environment, replacing allergen harbouring items such as pillows and carpets. However, such recommendations may be challenging for patients. In addition, cool compresses can be done to prevent rubbing of the eye. Ocular lubricating eye drops can be used to dilute the inflammatory agents in tears and wash away the allergen to reduce itching and to

prevent further worsening of symptoms.¹⁹

The mainstay of treatment is the use of lubricants, anti-histamines and mast cell stabilisers.^{16,20} These are indicated in all forms of disease. Steroids are to be given under proper medical care when the cornea is involved or the disease is very severe with itching.

Overuse of corticosteroids may cause steroid induced cataracts and glaucoma and may result in blindness. The drugs that are used are:

Mast cell stabilisers: disodium cromoglycate (not effective in acute stages), Nedocromil and Lodoxamide

Antihistamines: ketotifen, dual acting drugs such as olapatadine, azelastine, epinastine and bepotastine. Immediate symptomatic relief is possible with azelastine and epinastine, which are currently preferred.

Corticosteroids: such as prednisolone are given for a short duration during acute allergic disease; oral steroids or supratarsal injection of corticosteroids is required if the disease is severe.

Nonsteroidal anti-inflammatory agents (NSAIDs): ketorolac, diclofenac can be added to antihistamines. Steroid sparing agents such as Cyclosporine A, Tacrolimus are effective in severe AKC and VKC.

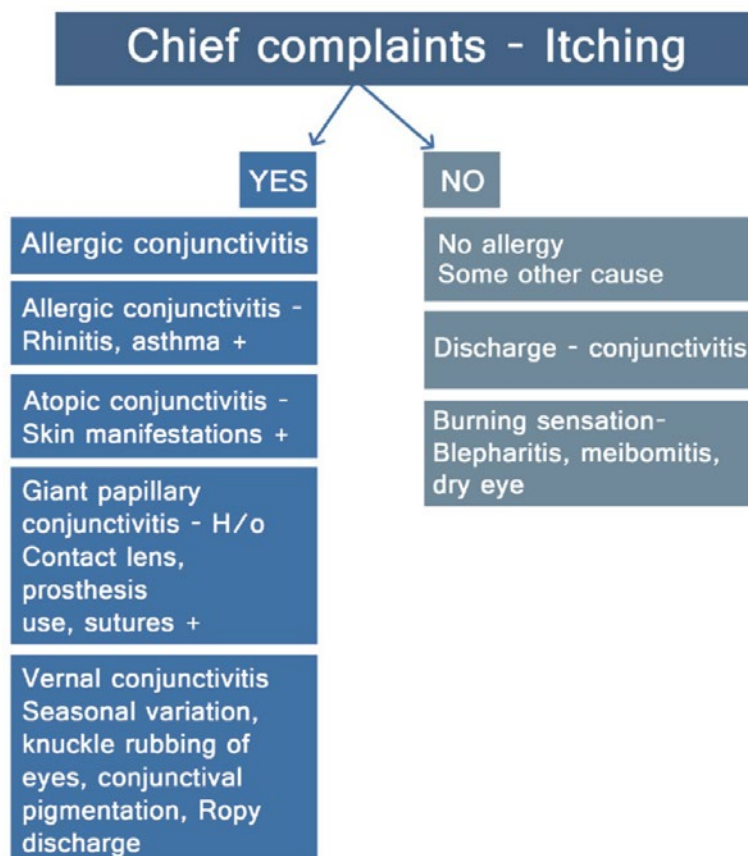
Conclusion

From a public health perspective, the number of patients being diagnosed with allergic conjunctivitis is increasing. However, not many studies are available from South East Asia, which give a complete picture of allergic eye disease. Severe conjunctivitis such as

VKC, being a disease of the young may increase the number of school dropouts in these countries. Economic costs for patients are high, sometimes necessitating the need for medications to continue for years.^{21,22} Management of the disease is very challenging and a multipronged approach with well-trained primary and

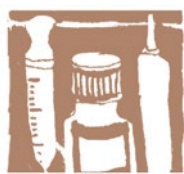secondary care personnel to educate patients or parents about the disease, especially about good general hygiene; avoidance of allergens; cold compression; change of environment; and judicious use of corticosteroids may improve ocular health in patients by leaps and bounds.

Figure 2. A guide to aid diagnosis of allergic conjunctivitis

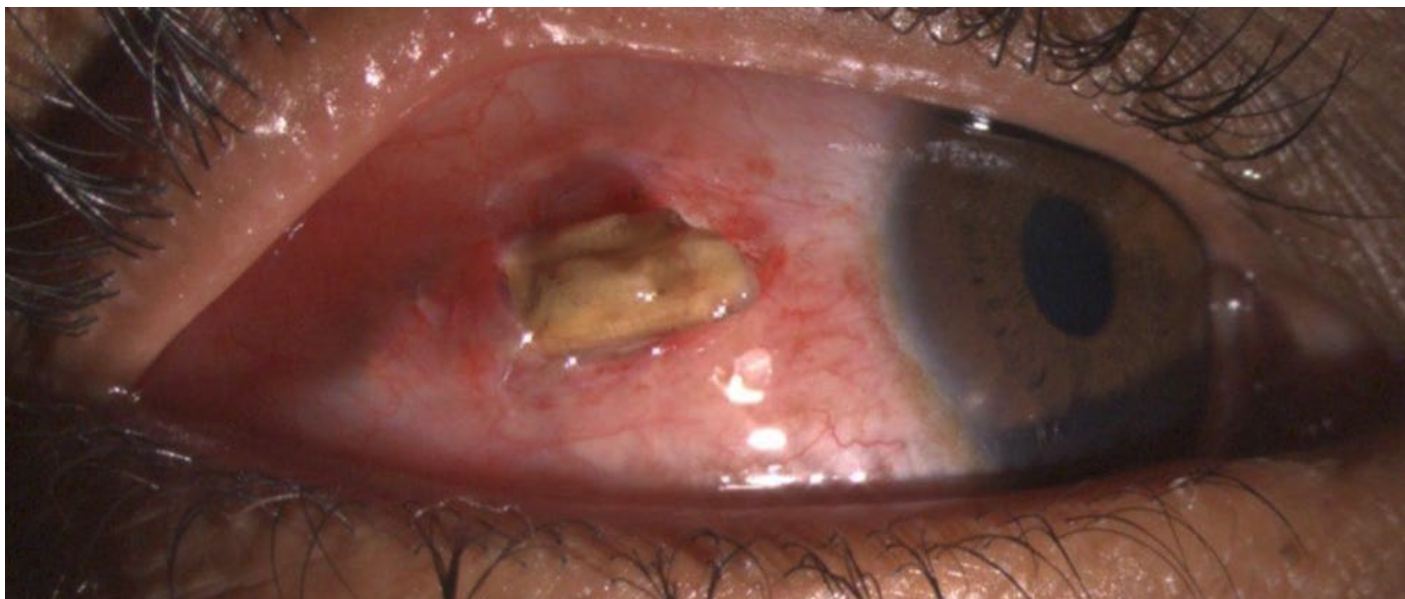

References

- Bonini S, Bonini S, Lambiasi A, Marchi S, Pasqualetti P, Zuccaro O, et al. Vernal keratoconjunctivitis revisited: a case series of 195 patients with long-term followup. *Ophthalmology*. 2000 Jun;107(6):1157-63.
- So RA, Mufti A. Vernal Keratoconjunctivitis in Kashmir: A temperate zone. *International ophthalmology*. 2016 Dec;36(6):875-879. Epub 2016 Mar 10.
- Ehlers WH, Donshik PC. Allergic ocular disorders: a spectrum of diseases. *The CLAO journal : official publication of the Contact Lens Association of Ophthalmologists, Inc*. 1992 Apr;18(2):117-24.
- La Rosa M, Lionetti E, Reibaldi M, Russo A, Longo A, Leonardi S, et al. Allergic conjunctivitis: a comprehensive review of the literature. *Italian journal of pediatrics*. 2013;39:18.
- Buckley RJ. Vernal keratoconjunctivitis. *International ophthalmology clinics*. 1988 Winter;28(4):303-8.
- Pokharel N, Shah DN, Choudhary M. Vernal keratoconjunctivitis: modes of presentation in Nepalese population. *Kathmandu University medical journal*. 2007 Oct-Dec;5(4):526-30.
- Saboo US, Jain M, Reddy JC, Sangwan VS. Demographic and clinical profile of vernal keratoconjunctivitis at a tertiary eye care center in India. *Indian journal of ophthalmology*. 2013 Sep;61(9):486-9.
- Ahmed A, Minhas K, Micheal S, Ahmad F. Prevalence of skin test reactivity to aeroallergens in the Pakistani population. *Public health*. 2011 May;125(5):324-6.
- Kansakar I. Profile of vernal keratoconjunctivitis in Nepal: a hospital based study. *Nepal Medical College journal : NMCJ*. 2011 Jun;13(2):92-5.
- Leonardi A, Piliego F, Castegnaro A, Lazzarini D, La Gloria Valerio A, Mattana P, et al. Allergic conjunctivitis: a cross-sectional study. *Clinical and experimental allergy : journal of the British Society for Allergy and Clinical Immunology*. 2015 Jun;45(6):1118-25.
- Katelaris CH. Ocular allergy in the Asia Pacific region. *Asia Pacific allergy*. 2011 Oct;1(3):108-14.
- Ukponmwan CU. Vernal keratoconjunctivitis in Nigerians: 109 consecutive cases. *Tropical doctor*. 2003 Oct;33(4):242-5.
- De Smedt S, Wildner G, Kestelyn P. Vernal keratoconjunctivitis: an update. *The British journal of ophthalmology*. 2013 Jan;97(1):9-14.
- Rao SK, Padmanabhan P. Perilimbal conjunctival pigmentation in vernal keratoconjunctivitis: a new sign. *Cornea*. 2002 May;21(4):432.
- Cameron JA. Shield ulcers and plaques of the cornea in vernal keratoconjunctivitis. *Ophthalmology*. 1995 Jun;102(6):985-93.
- Schmid KL, Schmid LM. Ocular allergy: causes and therapeutic options. *Clinical & experimental optometry*. 2000 Sep-Oct;83(5):257-70.
- Dart J. Corneal toxicity: the epithelium and stroma in iatrogenic and factitious disease. *Eye*. 2003;17(8):886-92.
- Kok YO, Tan GF, Loon SC. Review: keratoconus in Asia. *Cornea*. 2012 May;31(5):581-93.
- Hingorani M, Lightman S. Therapeutic options in ocular allergic disease. *Drugs*. 1995 Aug;50(2):208-21.
- Gokhale NS. Systematic approach to managing vernal keratoconjunctivitis in clinical practice: Severity grading system and a treatment algorithm. *Indian journal of ophthalmology*. 2016 Feb;64(2):145-8.
- Pitt AD, Smith AF, Lindsell L, Voon LW, Rose PW, Bron AJ. Economic and quality-of-life impact of seasonal allergic conjunctivitis in Oxfordshire. *Ophthalmic epidemiology*. 2004 Feb;11(1):17-33.
- Gupta R, Sheikh A, Strachan DP, Anderson HR. Burden of allergic disease in the UK: secondary analyses of national databases. *Clinical and experimental allergy : journal of the British Society for Allergy and Clinical Immunology*. 2004 Apr;34(4):520-6.



Ocular surface injuries & management



(c) R P Centre of Ophthalmic Sciences, AIIMS

Clinical photograph of a case of conjunctival laceration with a foreign body



Anubha Rathie

Senior Resident, Cornea, Cataract and Refractive surgery services, Dr R P Centre of Ophthalmic Sciences, AIIMS



Rajesh Sinha

Additional Professor, Cornea, Cataract and Refractive surgery services, Dr R P Centre of Ophthalmic Sciences, AIIMS



Neelima Aron

Senior Resident, Cornea, Cataract and Refractive surgery services, Dr R P Centre of Ophthalmic Sciences, AIIMS



Namrata Sharma

Professor, Cornea, Cataract and Refractive surgery services, Dr R P Centre of Ophthalmic Sciences, AIIMS

Introduction

The term 'ocular surface' was first defined by Thoft in 1987 as a combined unit including the cornea, conjunctiva, lacrimal glands and eyelids. Gibson further described this term in 2007 to include the surface and glandular epithelia of the cornea, conjunctiva, lacrimal gland, accessory lacrimal glands, meibomian glands and the eyelashes with their associated glands of Moll and Zeis along with the nasolacrimal duct.^{1,2} These components of the ocular surface are connected with a

continuous epithelium.

Being the most exposed part of the eye, the ocular surface is highly prone to injury. This article covers the spectrum of various ocular surface injuries and their management.

Classification

Ocular surface injury is a broad term which includes the following:

- Ocular surface chemical and thermal burns or injuries
- Conjunctival laceration
- Corneal perforation
- Eyelid laceration

Ocular surface chemical and thermal burns

Chemical injury may involve the ocular surface to a variable degree depending on the nature of the chemical agent, duration of exposure, concentration and volume of the agent. Host factors such as the nature and health of the ocular surface itself also plays an important role in deciding vulnerability of the surface to injury.

Most of the ocular surface chemical burns are due to either acids or alkalis. Alkali burns account for two-thirds of these.³ A majority of these burns occurs in young males with increased risk of exposure to chemicals in the workplace.

Alkali burns: The common alkaline sources include ammonia, lime or calcium hydroxide, lye or sodium hydroxide and magnesium hydroxide. The most common alkali causing ocular surface burns is lime while the most severe is ammonia. Ammonia, found in fertilisers and floor cleaners, has the most rapid penetration into the surface due to its lipid as well as water solubility. Alkali burns are more severe than acid burns as they lead to saponification of cell membranes and intercellular bridges facilitating rapid penetration into the deeper layers and into aqueous and vitreous cavities. Alkali burns cause stimulation of nerve endings of cornea and conjunctiva and hence are more painful.⁵

Acid burns: Sulphuric acid is the most common acid implicated in acid induced ocular surface burns. Hydrofluoric acid leads to the most severe burns as it is highly reactive with rapid and deep penetration just like alkalis. Acids in general cause less severe burns as compared to alkalis. They lead to coagulation and precipitation of proteins which in itself acts as a physical barrier, thus preventing further penetration of the agent.

Several classification systems have been suggested and proposed for ocular surface chemical injuries. Prominent ones include Hughes classification⁴ (1946), Roper-Hall classification⁵ (1965) and Dua's classification⁶ (2001).

Continues overleaf ➤



Table 1a. Roper-Hall classification

Grade	Prognosis	Cornea	Conjunctiva/ limbus
I	Good	Corneal epithelial damage	No limbal ischemia
II	Good	Corneal haze, iris details visible	1/2 limbal ischemia
III	Guarded	Total epithelial loss, stromal haze, iris details obscured	1/3-1/2 limbal ischemia
IV	Poor	Cornea opaque, iris and pupil obscured	>1/2 limbal ischemia

Table 1b. Dua's classification

Grade	Prognosis	Clinical findings	Conjunctival involvement	Analogue scale
I	Very good	0 clock hours limbal involvement	0%	0/0%
II	Good	≤3 clock hours limbal involvement	≤30%	0.1-3/ 1-29.9%
III	Good	>3-6 clock hours limbal involvement	>30-50%	3.1-6/ 31-50%
IV	Good to guarded	>6-9 clock hours limbal involvement	>50-75%	6.1-9/ 51-75%
V	Guarded to poor	>9-12 clock hours limbal involvement	>75-<100%	9.1-11.9/ 75.1-99.9%
VI	Very poor	Total (12 clock hours) limbal involvement	100%	12/100%

These classification systems hold true for cases of acute chemical injuries. In chronic cases with already established sequelae of chemical burns, the ocular surface health may be graded using the Holland-Mannis classification system.

The two commonly used classification systems, Dua's (2001) and Roper-Hall (1964) are summarised in Table 1a and Table 1b.^{5,6} The Roper-Hall classification system has classified all burns with more than 50% limbal ischemia in Grade IV. This

presents as a limitation in the prognostication of the burns according to grade as the prognosis is highly variable in burns with just 50% limbal ischemia as compared to burns with total limbal ischemia. Dua's classification in 2001 addressed this limitation and classified ocular surface chemical burns based on the clock hours of conjunctival and limbal involvement.

Clinical features of ocular surface chemical burns: In the acute stage up to one week post injury, ocular surface chemical burns usually pres-

ent with peri limbal ischemia (Figure 1a), corneal and conjunctival epithelial defects (Figure 1b) and retained chemical particles especially in the fornices (Figure 1c). Milder burns show re-epithelialisation gradually with or without treatment. More severe burns may develop complications such as persistent epithelial defects, dry eye, symblepharon, ankyloblepharon, cicatricial entropion or ectropion, and in rare and severe cases corneo scleral melt.

Figure 1. Clinical presentation of acute chemical injury

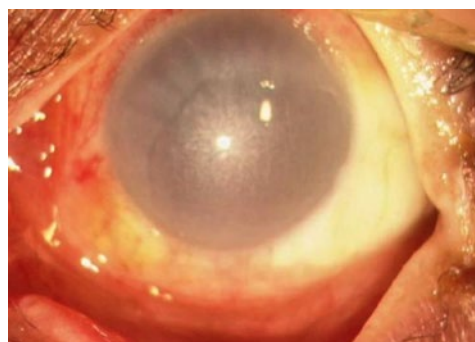


Figure 1a. Perilimbal ischemia

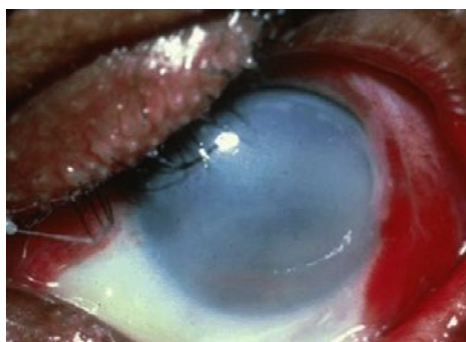

Fig 1b. Persistent epithelial defect

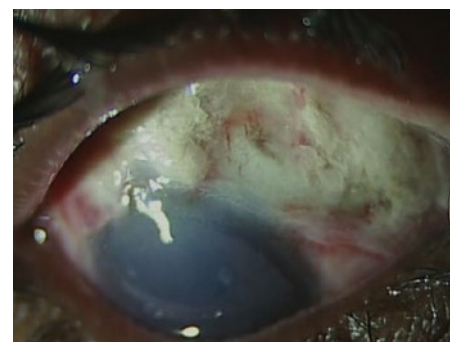

Fig 1c. Retained chemical particles in superior fornix

Continues overleaf ►

Figure 2. Impact of a simple limbal epithelial transplantation (SLET)

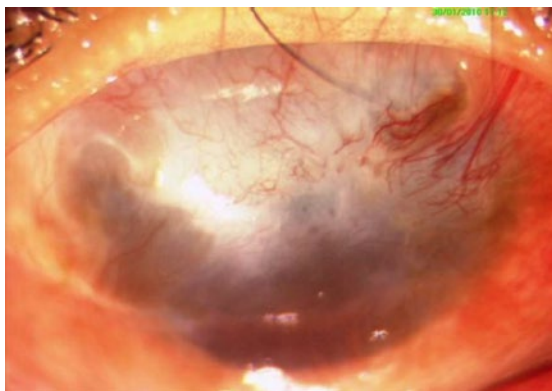


Figure 2a. A pre-operative case of chronic chemical injury with total LSCD

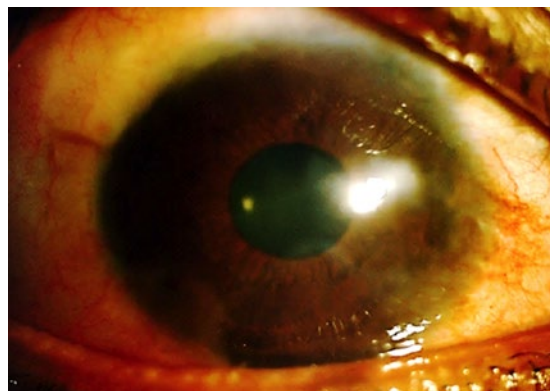


Figure 2b. A post-operative case of chronic chemical injury with total LSCD

Management of ocular surface

chemical burns: Ocular surface chemical burn is a medical emergency. Immediate irrigation of the eye should be done with clean running water, ringer lactate or normal saline until the pH of the ocular surface is neutralised. This has to be meticulously done using double eversion of the eyelids.

Timely treatment should then be instituted. Medical treatment includes topical antibiotics, cycloplegics, topical steroids, topical sodium ascorbate 10%, topical sodium citrate 10%, oral doxycycline, oral ascorbate and tear substitutes.⁷

Amniotic membrane transplantation is beneficial in moderate to severe chemical burns. It promotes re-epithelialisation, decreases the incidence of symblepharon formation, and decreases inflammation.⁸

In chronic cases with already established limbal stem cell deficiency or symblepharon formation, ocular surface rehabilitation may be required with symblepharon release with or without amniotic membrane transplantation.

Limbal stem cell transplantation may be done using fellow eye limbal stem cells or cadaveric limbal stem cells. Simple limbal epithelial transplantation (SLET) has been done with favourable outcomes in such cases (Figure 2a and Figure 2b).

Conjunctival laceration

Conjunctival laceration may occur following blunt or penetrating trauma. It presents with chemosis and subconjunctival haemorrhage. In such cases, it is important to rule out underlying scleral perforation. The fundus should be examined for any retinal tear or intraocular foreign body. An ultrasound may be done for the posterior segment evaluation. Such cases are managed with observation and topical antibiotics in mild cases and in large lacerations, surgical repair may be needed using 8-0 vicryl suture (Figure 3).

Corneal perforation

Corneal lacerations and perforations represent approximately 1 in 10 of ocular traumatic injuries presenting

in an emergency medical setting. There may be associated adnexal injuries, and /or scleral perforation. The major goals of management of a corneal perforation are to remove any contaminants in the wound area, repair the tear and maintain the water tight integrity of the globe. Corneal perforation may also be associated with a foreign body (Figure 4).

Partial thickness lacerations may heal on their own with time. Such cases may require patching in the immediate phase followed by topical antibiotics. Full thickness lacerations may be repaired using interrupted 10-0 monofilament nylon sutures. In case of associated scleral involvement, the scleral wound should also be sutured using 6-0 vicryl suture. In case of uveal prolapse, the uveal tissue that is not necrotic and has protruded for less than 24 hours may be repositioned back or and any old or necrotic prolapsed tissue carefully abscised. Other than conventional interrupted sutures, biological glue has also been used to seal the perforations especially those with tissue defect.

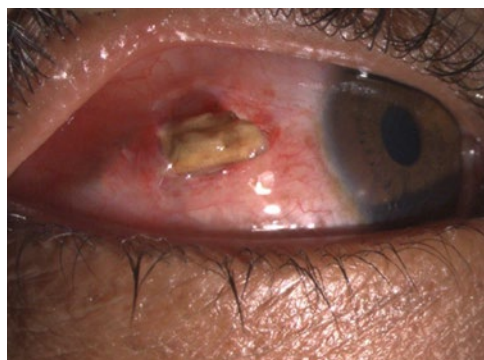

Figure 3. Conjunctival laceration with a wooden foreign body

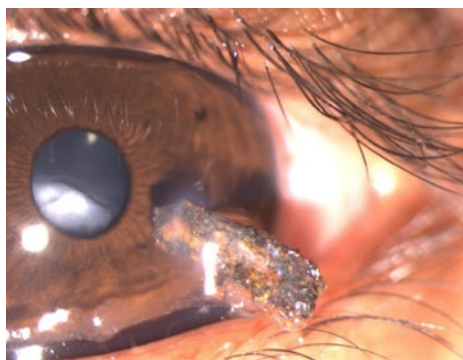

Figure 4. Corneal perforation with a metallic foreign body

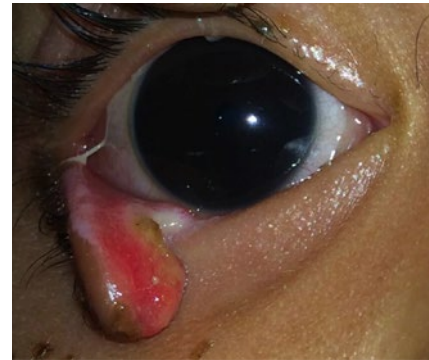

Figure 5. Medial eyelid laceration involving the canaliculus

Several studies have shown the beneficial effect of isobutyl cyanoacrylate glue for treatment of corneal perforations with tissue defect up to 3 mm.⁹⁻¹⁰

While suturing a corneal perforation, it is important to identify the major landmarks, especially limbus. It is advisable to preserve as much anatomy as possible and not over excise. The technique is to progressively halve the wound while passing sutures. They should be at 90° depth in the cornea. 'No touch technique' while passing sutures ensures a maintained anterior chamber during suturing. The central suture bites should be smaller and the length of suture should increase as one goes towards periphery.

For corneo scleral lacerations, it is important to perform a 360 degree peritomy and see the extent of scleral involvement, following which the limbus is secured with vicryl or monolament nylon suture. Corneal sutures are placed as described above. Scleral wound is closed using 'close as you go' or zippering technique. Disinsertion and reinsertion of recti may be required in posterior tears.

Eyelid lacerations

Eyelids and lacrimal system are as much a part of the ocular surface as the cornea and conjunctiva. Simple eyelid lacerations, which are horizontal follow skin lines and involve less than 25% of the lids, usually heal well even without suturing. Larger lid

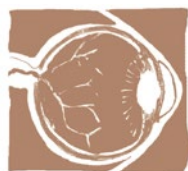lacerations require surgical repair. Uncomplicated lid lacerations with no lacrimal system involvement can be repaired using interrupted silk sutures. In case of medial lid injuries (Figure 5) with damage to the lacrimal system, canalicular repair is required along with lid laceration repair.

Conclusion

Ocular surface injuries are fairly common owing to vulnerability of the exposed ocular surface to trauma. They range from ocular surface chemical burns, conjunctival laceration, corneal perforation and eyelid laceration. Effective and timely management of these types of injuries is essential for maintaining the integrity of the ocular surface.

References

- 1 Gipson IK. The Ocular Surface: The Challenge to Enable and Protect Vision. *Investigative ophthalmology & visual science*. 2007;48(10):4390-4398
- 2 Kinoshita S, Adachi W, Sotozono C, et al. Characteristics of the human ocular surface epithelium. *Prog Retin Eye Res*. 2001;20:639-673
- 3 Morgan SJ. Chemical burns of the eye: causes and management. *Br J Ophthalmol* 1987; 71:854-857
- 4 Hughes Jr WF. Alkali burns of the cornea. I. Review of the literature & summary of present knowledge. *Arch Ophthalmol*. 1946; 35: 423-449
- 5 Roper-Hall MJ. Thermal and chemical burns. *Trans Ophthalmol Soc UK* 1965;85:631-53
- 6 Dua HS, King AJ, Joseph A. A new classification of ocular surface burns. *Br J Ophthalmol* 2001;85:1379-83
- 7 Haddox IL, Pster RR, Yuille-Barr D. The efficacy of topical citrate after alkali injury is dependent on the period of time it is administered. *Invest Ophthalmol Vis Sci* 1989; 30: 1062-1068
- 8 Meller D, Pires RTF, Mack RJS, Figueiredo F, Heiligenhaus A, Park WC et al. Amniotic membrane transplantation for acute chemical or thermal burns. *Ophthalmology* May;107(5):980-9 2000
- 9 Vote BJ, Elder MJ. Cyanoacrylate glue for corneal perforations: a description of a surgical technique and a review of the literature. *Clinical & Experimental Ophthalmology* 2000, 28(6):437-442
- 10 Khalifa YM et al. Management of nontraumatic corneal perforation with tectonic drape patch and cyanoacrylate glue. *Cornea*. 2010 Oct;29(10):1173-5



Prevention of traumatic corneal ulcer in South East Asia



(c) M Srinivasan/ AECs

Country principal investigator and lead principal investigator with village health workers in Bhutan



Dr. M. Srinivasan
Director Emeritus, Aravind Eye
Care, Madurai, Tamil Nadu
India.

Introduction

Corneal ulceration is a leading cause of visual impairment globally, with a disproportionate burden in developing countries. It was estimated that 6 million corneal ulcers occur annually in the ten countries of South East Asia region encompassing a total population of 1.6 billion.¹ While antimicrobial treatment is generally effective in treating infection, "successful" treatment is often associated with a poor visual outcome.

The scarring that accompanies the resolution of infection leaves many eyes blind. Thus, prevention of corneal ulceration is important to reduce morbidity associated with corneal ulceration in countries grouped

under South Asian Association for Regional Cooperation (SAARC). Traditional infectious causes of blindness, such as trachoma, onchocerciasis, and leprosy, are declining, and soon the majority of corneal blindness will be due to microbial keratitis. Most corneal ulcers occur among agricultural workers in developing countries following corneal abrasion.

Several non-randomised prevention studies conducted before 2000 (Bhaktapur Eye Study)² and during 2002 to 2004 in India, Myanmar, and Bhutan by World Health Organization (WHO), have suggested that antibiotic ointment applied promptly after a corneal abrasion could lower the incidence of ulcers, relative to neighbouring or historic controls.³⁻⁴ Prevention of traumatic corneal ulcer adopting the Bhaktapur model in a multicountry study in India, Bhutan, Myanmar during 2002 to 2004 was sponsored by WHO.

Methods

The manpower utilised for this multi country study to identify ocular injury and treat corneal abrasion is given below:

Bhutan: Volunteer Village Health Workers (VVHW) of the Government were utilised to identify ocular injury and treat corneal abrasion

Myanmar: Village Health Workers (VHW) of the health department

India: paid village volunteers were utilised

Inclusion criteria

- Resident of study area
- Corneal abrasion after ocular injury, confirmed by clinical examination with fluorescein stain and a blue torch
- Reported within 48 hours of the injury
- Subject aged >5 years of age

Table 1. Study design, sample size and results

	Bhutan	India	Myanmar
Study design	Unmasked	Randomized double masked trial	Unmasked
Sample size	111 corneal abrasions	338 corneal abrasions	111 corneal abrasions
Results of Multicountry study			
No. of ocular injuries	135	1365	273
No. of corneal abrasions	115	409	126
No. of eligible corneal abrasions	115	374	126
Adverse events	Nil	4	Nil

Continues overleaf ►

Exclusion criteria

- Subject not a resident of study area
- Presence of clinically evident corneal infection
- Penetrating corneal injury or stromal laceration

- Bilateral ocular trauma

The study was approved by Institutional Review Boards (IRB) from all the three countries.

Treatment Protocol

In general, corneal abrasions are treated with topical antibiotics and cycloplegics. In few centres bandaging the affected eye is practiced but it is controversial. 1% chloramphenicol ointment and 1% clotrimazole ointment was used. In Bhutan only chloramphenicol was used. In Myanmar both antibiotic and antifungal ointment applied but in India it was randomised and one arm was masked to receive both and in the other arm chloramphenicol and placebo ointment were used to find out whether antifungal prophylaxis is needed to prevent fungal ulcer. Frequency of application of all the drugs was three times a day for three days, supervised by village eye workers for compliance.

Conclusion of multi-country study

This model of delivering eye care services through trained village eye workers and grass root health workers is a replicable model for any developing country, especially for SAARC countries. (Figure 1a). Follow up rate on the third day at all centres were more than 98%. No case of serious adverse event was reported. Developing bacterial and fungal corneal ulcer using 1% chloramphenicol ointment in 96% of patients could be prevented if reported within 24 hours.

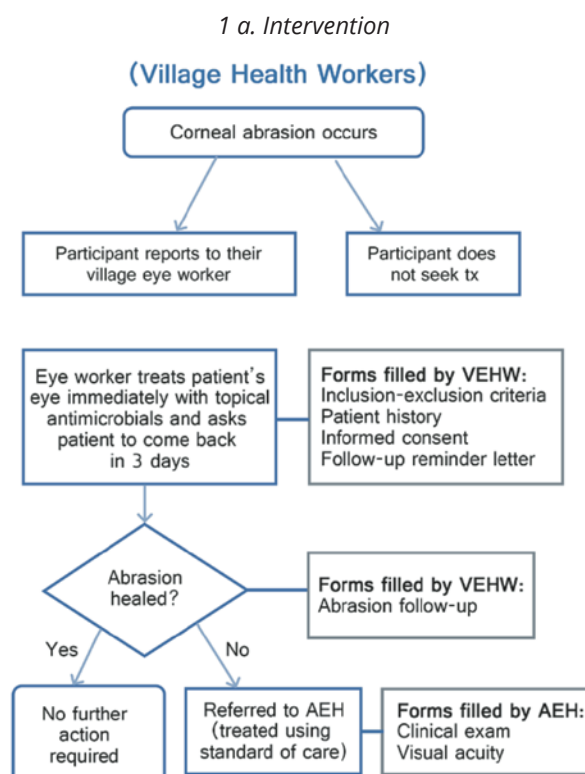
In Madurai, South India, a clinical trial during the same period demonstrated that abrasions randomised to topical antibacterial and antifungal prophylaxis were not significantly less likely to develop fungal ulcers than those randomised to antibacterial ointment alone, even though the region had a high incidence of fungal infection. This same trial also found that the incidence of ulcers in villages outside the prophylaxis programme one was far higher; these control villages were neighbouring, but not randomised. To address this issue, we proposed a community randomised trial comparing villages randomised to receive an intervention consisting of a trained village eye worker identifying, escorting or referring

the patient from intervention villages to the nearest vision centre run by Aravind Eye Care System. There a trained vision technician would confirm corneal abrasion, provide 1% chloramphenicol ointment to the eligible, enrolled patients in Madurai district. Control villages received no additional intervention. The primary outcome of corneal ulcer prevention will be measured by baseline and annual population-based census performed in both intervention and control villages by masked examiners from baseline to 24 months. The examiners will examine the eyes of all households from intervention and non-intervention villages who are suspected of having a corneal ulcer or injury with torch light and magnifying loup.

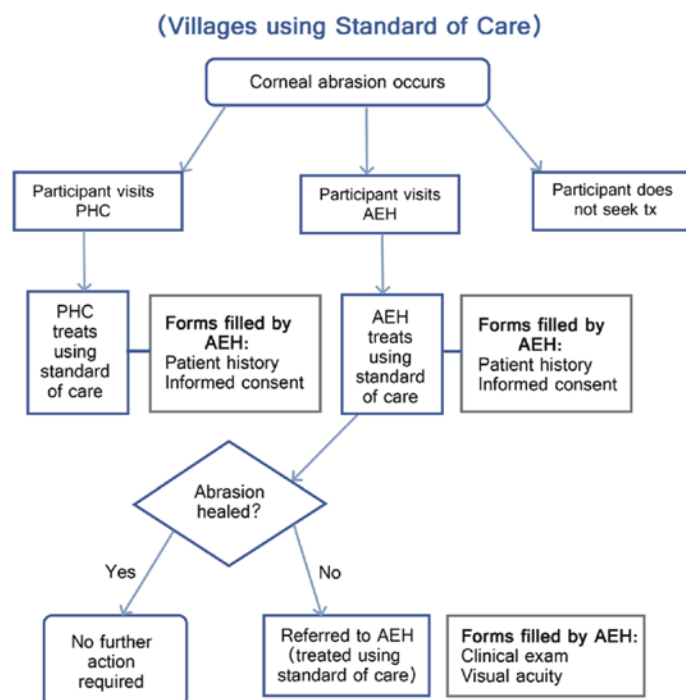
Each resident in the village will be examined for evidence of corneal opacity and asked about their ocular history.

Annual visits will occur in villages randomised to the intervention, an active promotion campaign will be undertaken to urge residents to notify the village eye health worker within 24 hours of ocular trauma. In control villages, abrasions and ulcers will be treated if they present to the vision centre or are found during annual monitoring visits, but active promotion of corneal abrasion care will not be offered.

Figure 1. Design of the study for intervention and control arms



1 b. Control



Methodology – phase II study

The study was designed in 2014 in consultation with F.I. Proctor Foundation, San Francisco. Enrollment began in January 2015 and ended in December 2016. 42 villages having approximately 92 thousand people involved in agriculture work were allotted. Randomisation was done to have 50% of the population for intervention (Figure 1b) and rest for non-intervention (Figure 1b). Data collection, entry, and analysis will be done at Aravind Eye Care System, Madurai and the project will be completed in 2017. Legal and ethical clearance was obtained from appropriate authorities. Details of the study design are in the flow chart. (Figure 1)

Primary outcome of the current study

The primary outcome will be the incidence of corneal ulceration in the two study arms as measured by corneal examination at the base hospital or vision centre with telemedicine facility. In this study 1% chloramphenicol ointment and 1% itraconazole

ointment is applied three times a day for three days and compliance would be checked by village health workers. Any adverse event will be informed to the study Principal Investigator (PI) or Aravind Eye Hospital and will be taken care at no cost to the participant.

Manpower

20 paid village workers who have completed school and are able to fill study forms in English and reside in the study village were enrolled. Two supervisors well-experienced in rural eye care work will oversee the workers.

Steps in managing programme

- Workers attend one week training at Aravind Eye Hospital prior to the study to learn basic anatomy of the eye, common corneal and external diseases, ocular injuries, vision testing, use of fluorescein strip, simple eye medicines application and; attend twice-yearly refresher training throughout the course of the study.
- Promote awareness of corneal abrasion intervention in intervention villages only
- Accessible by villagers via mobile phone

- Conduct eye examination to diagnose corneal abrasion and/or ulcer
- Assist treatment at vision centre for corneal abrasion, and follow up with the patient for three days at the village to ensure compliance
- Motivate patient to return for follow-up three days after treatment, assess compliance and perform examination
- If the patient develops a corneal ulcer or adverse reaction, he/she is referred to Aravind Eye Hospital for immediate treatment.

Verbal consent must be obtained from all individuals who present to the village eye worker to receive study medication. Possible risks and benefits of receiving the treatment will be explained. For patients under 18, both the child and one parent or guardian will provide consent for the child's participation.

We believe the results of this study may emerge as a replicable model to prevent traumatic corneal ulcer, and reduce corneal blindness in South Asia.

References

- Whitcher J, Srinivasan M, Upadhyay M. Corneal blindness: a global perspective. *Bull World Health Organ.* 2001;79(3):214-221.
- Upadhyay M, Karmacharya P, Koirala S, et al. The Bhaktapur eye study: ocular trauma and antibiotic prophylaxis for the

prevention of corneal ulceration in Nepal. *Br J Ophthalmol.* 2001;85:388-392.

- Getshen K, Srinivasan M, Upadhyay M, Priyadarsini B, Mahalaksmi R, Whitcher J. Corneal ulceration in South East Asia. I: A model for the prevention of bacterial ulcers at the village level in rural Bhutan. *Br J Ophthalmol.* 2006;90:276-278.

- Maung N, Thant C, Srinivasan M, et al. Corneal ulceration in South East Asia II: A strategy for the prevention of fungal keratitis at the village level in Burma. *Br J Ophthalmol.* 2006;90:968-970.

"Save your eyes for thirty Rupees" : A case study



c) Asim Sil

A farm labourer wears protective glasses during threshing. INDIA



Asim Kumar Sil, DO, DNB, MSc

Netra Niramay Niketan,
Vivekananda Mission Ashram,
Chaitanyapur, Purba Medinipur,
West Bengal

Introduction

Various types of agricultural eye injuries are common in India. The prevalence of ocular injury in agricultural workers is unknown in India but data from a few studies suggest that this is quite common.^{1,2} Injury from sugarcane leaf is quite common in Northern and Western India, grape vine injury is common in central and south India.³ Paddy grain injury of cornea is very common in coastal India where rice is grown as the main crop. In recent times, the incidence of paddy grain injury has gone up because mechanical (paddle or power driven) threshers have replaced the traditional practice of manual separation of grains by beating the plant against a raised wooden platform.⁴ This article depicts the experience of a community-based intervention for preventing corneal injury in agricultural workers in a rural area of West Bengal.

Paddy grain and the eye

Agriculture in West Bengal is the means of livelihood of about 65% population. Rice occupied almost 53% of the total agricultural crop of the state during 2007-2008.⁴

The age-old practice of separation of paddy grains from the plant used to be by hitting the tip of the plant against

a platform made of bamboo or wood. This process takes longer time and involves more manpower. Since the speed with which the grain comes out during separation is less, there is less chance of eye injury by the paddy. Now the process has been replaced by the use of mechanical threshers to do the same work in much shorter time and save resources.⁴

In most areas of West Bengal rice is grown in 3 different seasons. They are called Aus (autumn rice), Aman (winter rice) and Boro (summer rice). The sowing time of summer rice is November to February and harvesting time is March to June. The average yield of Boro is 50 – 60% higher than other two varieties.⁴ Plants grown in different seasons are not of the same length, varying from 100 to 190 cm.⁵ In the Southern part of Bengal one high yielding variety of rice is harvested during April-May. This plant is short in length and has a greater number of grains than the other ones. That is why cases of corneal abrasion are much more reported during April-May. One study from South India has reported a higher incidence of fungal keratitis occurring during the months corresponding to the harvest seasons, during which time infection from vegetative corneal injury may be more likely.⁶

During harvesting almost the entire family of a farmer is involved in the work. Mechanical threshers are usually operated by young men by feet and the tip of the plant is placed over the spin. Another person, usually a woman con-

stantly sweeps the ground to collect the grains at one place. Her face is usually closer to the machine and more prone to injury. Anybody, even a child moving close to the thresher may get injured.⁷

Farmers have a habit of covering the head and face with a piece of cloth to avoid dust but leave the eyes open while threshing. This practice keeps the eyes unprotected. The commonest mode of injury is abrasion of the cornea by rapidly moving seed. The most unfortunate sequel of this injury is development of fungal keratitis. Paddy grain has fine hair like structures over the outer coating, which is why the grains gets firmly anchored to the conjunctiva.

Sometimes the grain lodges inside the upper fornix and remains unnoticed, and in rare cases, it may start growing inside the eye.⁷ Treatment of fungal keratitis is difficult in rural locations, as the cases often report late and are complicated by the use of unknown eye drops or native medications. Most dangerous is the application of topical steroids which are sold over the counter in village medical shops without prescription, as steroids worsen fungal infections. Fungal culture facility is usually not available in rural situations and, antifungal medications if available are therefore used empirically.

Application of too many drops often reduces the efficacy of antibiotics. All these issues contribute to unilateral corneal blindness after paddy grain injury and often patients are of active working age. Morbidity, loss of time, work and ultimate of loss of vision

make paddy grain injury a public health issue.

Prevention of paddy injury – community intervention

The most obvious way of preventing this corneal injury is protecting the eyes at the time of threshing. Wearing plastic goggles was considered to be a cheap and easy option. Education materials were produced to propagate the use of protective glass. Posters were displayed in places that farmers visit usually. Eye health talks were organized in different occasions and festivals. One short public education video “only 30 Rupees to save your Vision,” was developed in local language to motivate people to wear glasses (plastic goggles in India cost Rupees 30 or half a Dollar). This video was shown in different places including the local cable network. A compact disc of this six minute film was distributed among volunteers who used it locally. This video is widely used during eye donation awareness meetings also.

The most effective way of communication was interactive meeting with the farmers. Farmers’ co-operatives were selected for the meetings. Every large village in this part of Bengal has one co-operative where farmers get agricultural assistance and the evening is the suitable time to get them there. Interactive meetings started with the thought provoking video and was followed by discussions. It was found that many farmers do the threshing in the evening using electric lights. Sometimes it is overtime work, or to avoid daytime heat. Initially dark glasses (used after cataract surgery) were promoted to avoid corneal abrasion. But these were unsuitable for evening use, so the dark

glasses were replaced with plain ones without increasing the cost. This white goggle had more acceptances, especially among women. The price could be kept under INR 30. The message that any kind of spectacle is good to protect the eyes was conveyed through this intensive approach.

Measuring the impact

Sutahata and Mahishadal Blocks of East Medinipur district in West Bengal were selected for intensive campaigning few weeks before the harvesting time. These blocks were selected because of the proximity to the hospital. This is also the closest eye care facility for the villagers. The population of these blocks was approximately 356,000.

We looked at the hospital data of all cases of corneal ulcers from these two locations as well as from Purba and Paschim Medinipur districts served by our hospital. A decreasing trend is observed over time in those two selected blocks.

Discussion

This awareness campaign could have made some impact in preventing corneal injury and reduction of corneal ulcer. There could be various reasons for reduction in number of walk in patients with corneal ulcers in the clinic. Awareness campaign is possibly one contributing factor.

There are always barriers in the usage of safety eyewear amongst workers. In one study from central India about three-fourths of the workers reported using it all or most of the time during work.⁸ Despite knowing that protective eyewear devices offer safety from work-related injuries, workers

do not tend to use them for multiple reasons. These include some blurring of vision, discomfort, fogging, unusual appearance, people making fun of them, slipping of the goggles due to sweat and slowing work pace.

Prevention of ocular injuries in agriculture workers will reduce the incidence of microbial keratitis amongst them. Srinivasan et al demonstrated that treating corneal abrasions with antibiotic ointment by health workers at the village level significantly reduced the incidence of bacterial and fungal corneal ulcers, but primary prevention of injury is always the best.⁹ It is all about developing the attitude of adopting safety measures. Constant effort of educating the community will result in consciousness about eye safety and develop peer pressure to wear protective goggles. Providing protective goggles at an affordable cost should complement this effort. Also, the manufacturers of the threshers have a responsibility in ensuring safety of the agricultural workers by modifying the design.

Awareness will always remain as the main strategy for prevention of eye injury. The current approach is interactive and participatory. The experience with a small defined population encourages us to scale up the campaign involving all stakeholders and making the goggles available locally.

Acknowledgement

Dr. Samar K. Basak, Director, Disha Eye Hospitals, Barrackpore, West Bengal
Ms. Barnali Banerji, Assistant Director of Agriculture, Directorate of Agriculture, Kolkata, West Bengal.

Table 1. Number of cases of corneal ulcers in areas where the community intervention was applied

Year	Sutahata Block	Mahishadal Block	Purba Medinipur District	Paschim Medinipur District
2009	48	60	687	244
2010	58	62	705	307
2011	69	69	703	312
2012	92	74	804	329
2013	126	58	852	336
2014	89	56	826	310
2015	46	48	875	360

References

- Nirmalan PK, Katz J, Tielsch JM, Robin AL, Thulasiraj RD, Krishnadas R, et al. Ocular trauma in rural south Indian population. The Aravind Comprehensive Eye Survey. *Ophthalmol*2004;111:1778-81.
- Krishnaiah S, Nirmalan PK, Shamanna BR, Srinivas M, Rao GN, Thomas R. Ocular trauma in rural population of southern India: The Andhra Pradesh Eye Disease Study. *Ophthalmol*2006;113:1159-64.
- Goel R, Malik KP, Goel A, Sharma N, Aggarwal A, Nepal J. *Ophthalmol. Agriculture related corneal injuries*.2013 Jan-Jun;5(1):45-9.
- B. Adhikari et al, Rice Research Station, Govt. of West Bengal, Status Paper on Rice in West Bengal, 2010
- P K Mishra & Anjan Kumar Sinha, Rice Diversity in Bankura District of West Bengal, *Bioscience Discovery* 3(3): 284 -287, Nov. 2012
- Lin CC1, Lalitha P, Srinivasan M, Prajna NV, McLeod SD, 9. Acharya NR, Lietman TM, Porco TC Cornea. Seasonal trends of microbial keratitis in South India. 2012 Oct;31(10):1123-7.
- Asim Kumar Sil, Grain Found Growing in the Eye, *Community Eye Health*. 2000; 13(34): 32.
- Samrat Chatterjee, Deepshikha Agrawal, Anupam Sahu,Dharmender Dewangan, Primary Prevention of Ocular Injury in Agricultural Workers with Safety Eye Wear:Proceedings of AIOC, 2012
- Srinivasan M, Upadhyay B, Priyadarshini B, et al. Corneal ulceration in south-east Asia III: Prevention of fungal keratitis at the village level in south India using topical antibiotics. *Br J Ophthalmol*2006;90:1472-5.